Percutaneous Treatment of a Native Vessel as a New Approach to the Management of a Giant Saphenous Vein Graft Aneurysm

Hashim HMS

A 60 year old gentleman with a background of hypertension and Coronary Artery Bypass Graft operation in 1994 presented with shortness of breath on exertion and pleuritic chest pain. A Computer Tomography (CT) scan showed an 8x6cm anterior mediastinal mass and a diagnosis of saphenous vein graft (to left circumflex artery) aneurysm (SVGA) was confirmed by a coronary angiogram. A cardiac Magnetic Resonance Imaging (MRI) scan demonstrated that the saphenous vein graft aneurysm was compressing the internal mammary artery graft and the pulmonary artery. Percutaneous coronary intervention to the native left circumflex artery by deploying a covered stent at the site of anastamosis of the graft outflow into the left circumflex was done. This was followed by occlusion of the aneurysm inflow by deploying a vascular plug. The patient recovered well and his symptoms improved.

Introduction:

Saphenous venous graft aneurysm is a rare complication of coronary artery bypass graft (CABG) surgery and commonly happens more than 10 years after the operation[1]. Although the first case was reported in 1975[2] there is no consensus on the management approach of SVG aneurysms because there are no large randomised controlled trials to compare conservative, surgical and percutaneous approaches. This case was unique because it was managed by deploying a covered stent into the native coronary artery rather than into the aneurysm itself. In addition, the confusion about the initial diagnosis of this case highlights the importance of awareness and suspicion of SVG aneurysm in patients with history of CABG. Also the size of the aneurysm was very large however SVG aneurysms more than 10cm have been reported[3,4,5]. Finally the compression of the internal mammary artery causing flow obstruction is uncommon however it has been reported in at least 2 case reports in 2012 both claiming that it was the first time it was reported[6,7].

Case report:

Presentation:

This was a 60 year old gentleman who presented with shortness of breath and pleuritic chest pain for 2 days prior to admission. He has a background of Hypertension and triple coronary artery bypass grafts in 1994 which involved left internal mammary artery graft to the left anterior descending coronary artery, saphenous vein graft to the left circumflex coronary artery and another saphenous vein graft to the right coronary artery. In 2007 he presented with worsening angina and a coronary angiogram done in 2008 showed blocked saphenous vein graft to right coronary artery but patent internal mammary artery graft to left anterior descending artery and patent saphenous vein graft to left circumflex artery. He refused surgery and his symptoms improved with medical management. Physical examination was unremarkable.

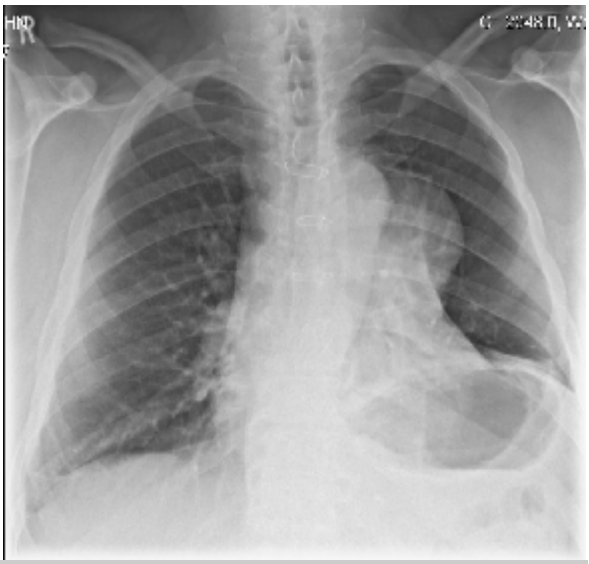

Fig 1 CXR showing a mediastinal mass

Investigations:

Initially a pulmonary embolism was suspected and the patient had a chest Xray which showed an anterior mediastinal mass with a differential of thymoma, lymph node or malignancy (figure 1). A computer tomography pulmonary angiogram (CTPA) was arranged and there were no pulmonary clots however, the CT chest showed an 8x6 cm left anterior mediastinal mass with a possibility that it might be an aneurysm (figure 2). Therefore a coronary angiogram was performed and it showed that the saphenous vein graft to the left circumflex was patent but leading to a huge aneurysm (figure 3). The internal mammary graft to the left anterior descending artery showed severe proximal narrowing with good anastamosis and run off and raised the suspicion of an external compression. The saphenous venous graft to the right coronary artery was occluded. The left ventricular function was moderately impaired. This was followed by a cardiac magnetic resonance scan which showed that the aneurysm was compressing the internal mammary graft and the main pulmonary artery.

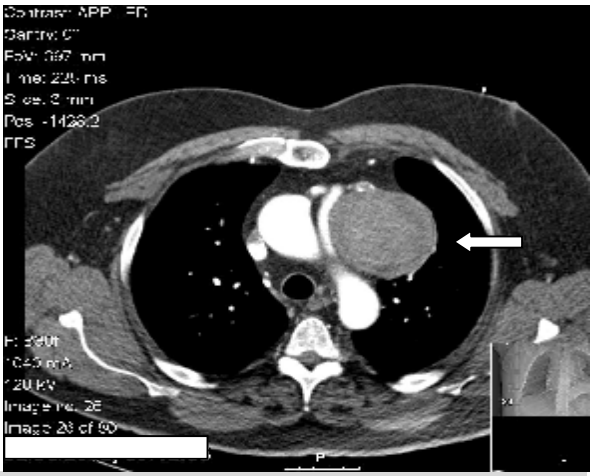

Fig 2 CT scan showing saphenous venous graft aneurysm

Treatment:

The case has been discussed in a multi disciplinary meeting and with the patient and the agreement was to adopt a percutaneous approach. The strategy was to deploy a covered stent to the left circumflex artery across the outflow of the saphenous venous graft followed by occlusion of the aneurysm inflow.

To support the stent delivery to the left circumflex native artery a balance middle weight (BMW) universal guide wire with guide liner 6F was used. A 2.0 x 20mm balloon pre dilatation was performed followed by deployment of 2.75 x 12 mm Bentley Innomed Be covered graft stent. There was an abnormal appearance distally so a 2.5 x 8mm resolute integrity Drug Eluting Stent (DES) was deployed distally with good results and restored the native circulation.

The next step was endovascular treatment of the saphenous vein graft aneurysm inflow. A 6F Left Coronary Bypass (LCB) guide and a Balance Middle Weight (BMW) wire were used to access the saphenous venous graft. There was a stenosis proximally and this was dilated with a 4 x 20 mm balloon. Then an anchor balloon was used to bring the guide catheter into the aneurysm sac and An Amplatzer vascular plug was then deployed across the stenosis prior to the aneurysm occluding the flow. An excellent result with aneurysm inflow occlusion was achieved.

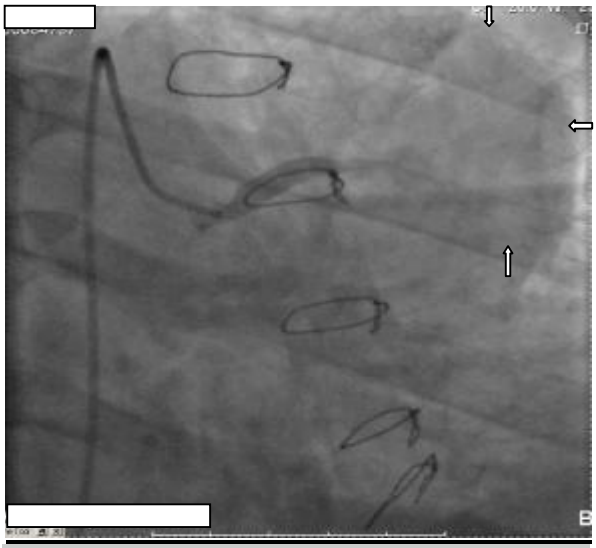

Fig3 Coronary angiogram showing giant aneurysm

Outcome:

The procedure was successful and the patient recovered without complications. Successful exclusion of the aneurysm was confirmed by imaging. The patient was seen in the outpatient clinic and his symptoms improved.

Discussion:

Saphenous vein graft aneurysm is a localized dilatation of the graft more than 1.5 times the diameter of the graft[8]. It is a late complication of coronary artery bypass graft operations that is usually diagnosed more than 10 years after the bypass operation[1]. A recent systematic review analyzing 209 patients reported an average of 13 years after the operation and 68% of cases presented after 10 years[1]. Our case was consistent with this report as it presented 18 years after the coronary artery bypass operation. A case series of more than 5500 grafts reported an incidence of 0.07%[9]. If its size exceeds 4cm it is considered a giant aneurysm[10]. The size of the saphenous vein graft aneurysm in this case was 8 x 6cm which makes it a relatively large aneurysm however there has been reports of aneurysms larger than 10cm[3,4,5].

The clinical presentation of saphenous vein graft aneurysm is very variable. However in the systematic review of 168 published cases chest pain/angina was reported in 46.6%, incidental finding in 32.5%, shortness of breath in 12.9% and myocardial infarction in 7.7%[6]. Less frequent presentations include heart failure, haemoptysis and arrhythmias[1]. Other complications include compression of adjacent structures, fistula formation and rupture of the aneurysm which may lead to haemopericardium, haemothorax or sudden death[1]. This case presented with a relatively common presentation which was shortness of breath on exertion and chest pain. However the magnetic resonance imaging revealed that the aneurysm was compressing the internal mammary artery graft which was consistent with the proximal narrowing in the internal mammary artery graft seen in the coronary angiogram (figure 4). This is a rare complication and only in 2012 two cases were reported to compress the internal mammary artery graft and jeopardise its patency[6,7].

The triad of chest pain, previous history of coronary artery bypass and a mediastinal mass raises the suspicion of saphenous vein graft aneurysm. There is no consensus on the best imaging modality but the systematic review reported that cardiac catheterization was used in 66.5%, CT scan in 60.3%, chest X-ray in 54.1 %, MRI in 12.9% and Echocardiogram in 28.2%[1]. The aneurysm can be seen in a chest X-ray as a mediastinal mass or in an echocardiography incidentally. The goals of further investigations should be to confirm the diagnosis, exclude complications and assess the patency of the graft as well as the rest of the coronary circulation. In our case the first suspicion occurred when a mediastinal mass was found in the chest X-ray but the X-ray report suggested a differential diagnosis of thymoma, lymph node or tumour so the CT scans were arranged on the basis of excluding malignancy and pulmonary embolism. After the CT scan result the patient had a coronary angiogram followed by a cardiac MRI.

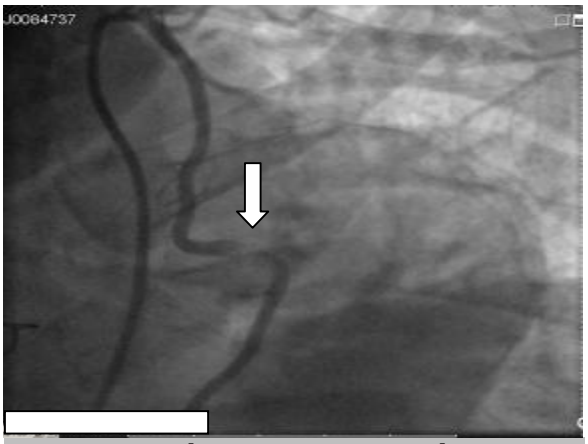

Fig 4 Proximal stenosis in internal mammary artery graft with good distal run off, suggesting external compression

Although the first case of a saphenous vein graft aneurysm was reported in 1975[2] there is no consensus on the management and decisions on the management are made on a case by case basis[1]. A case series of 13 patients concluded that surgical treatment is not better than conservative management in improving survival on the short term[9]. However, surgical intervention in symptomatic patients was recommended in a review of 16 patients treated surgically[11]. A systematic review of 168 patients reported that 58.4% were treated surgically, 20.1% were managed conservatively and only 15.8% were treated percutaneously but the 30 day and/or inhospital mortality was lower in the percutaneous group 6.1% compared to 23.8% in the conservative management and 13.9 in the surgical management groups[1].

Percutaneous management options include applying elastic coils, covered stents, thrombin injections or vascular plugs to the saphenous vein graft. Our case is unique because the approach was to treat the native coronary vessel and restore its patency and then exclude the aneurysm. This technique allows exclusion of a patent saphenous venous graft without sacrificing the myocardial perfusion. However, only selected cases will be suitable for native vessel angioplasty.

Conclusion:

- A patient who presents with the triad of previous CABG operation, chest pain and a mediastinal mass should be investigated for SVGA.
- This case confirms previous reports that giant SVGA can compress the internal mammary artery graft and jeopardize its patency.
- In selected cases, an attempt to treat the native coronary artery vessel supplied by the saphenous vein graft can be an attractive option and this case demonstrated that it can be successful.

References:

1. Ramirez FD, Ramirez FD, Hibbert B, Simard T, Pourdjabbar A, Wilson KR, Hibbert R, Kazmi M, Hawken S, Ruel M, Labinaz M, O'Brien ER. Natural History and Management of Aortocoronary Saphenous Vein Graft Aneurysms : A Systematic Review of Published Cases. Circulation. 2012;126:2248-2256
2. Riahi M, Mark Vasu C, Tomatis LA. Aneurysm of saphenous vein bypass graft to coronary artery. J Thoracic Cardiovasc Surg. 1975;70:358 –359.
3. Krishnasamy P, Gillespie JSJ, McGlinchey PG, Khan MM, Adgey AAJ. Giant true saphenous vein graft aneurysm causing cardiac compression: a rare cause of atrial flutter. Int J Cardiol. 2007;121:317–319.
4. Nolke L, McGovern E, Wood AE. Saphenous vein graft aneurysms; the true, false and ugly! Interact Cardiovasc Thorac Surg. 2004;3:631– 633.
5. Sura AC, Douglas JS. Percutaneous closure of giant saphenous vein graft aneurysm. JACC Cardiovasc Interv. 2010;3:784 –785.
6. Van Caenegem O, le Polain de Waroux JB, de Kerchove L, Coche E. Giant venous aneurysm jeopardising internal mammary arterial graft patency. Interact Cardiovasc Thorac Surg. 2012 Sep;15(3):540-1.
7. Khan R, Kakani N, Diamantouros P. Percutaneous closure of a saphenous vein graft aneurysm causing left internal mammary artery compression and left ventricular systolic dysfunction. JACC Cardiovasc Interv. 2012 Oct;5(10):1091-2.
8. Kelley MP, Carver JR. Coronary artery aneurysms. Journal of Invasive Cardiology. 2002 Aug;14(8):461–2.
9. Dieter RS, Patel AK, Yandow D, Pacanowski J, Bhattacharya A, Gimelli G, Kosolcharoen P, Russell D. Conservative vs. invasive treatment of aortocoronary saphenous vein graft aneurysms:

treatment algorithm based upon a large series. Cardiovasc Surg. 2003;11:507–513.
10. Topaz O, Rutherford MS, Key-Bojack S, Prinz AW, Katta S, Salter D, Titus JL. Giant aneurysms of coronary arteries and saphenous vein grafts: angiographic findings and histopathological correlates. Cardiovasc Pathol. 2005;14:298 –302.
11. Sareyyupoglu B, Schaff HV, Ucar I, Sundt TM 3rd, Dearani JA, Park SJ. Surgical treatment of saphenous vein graft aneurysms after coronary artery revascularization. Ann Thorac Surg. 2009;88:1801–1805.