High Output Cardiac Failure with Severe Tricuspid Regurgitation due to aquired Femoral Arteriovenous Fistula

DR. Saad A. Subahi, F.R.C.P , Consultant cardiologist , Ihab A.M.Ahmed F.R.C.S Consultant surgeon, Ribat University Hospital, Khartoum, Sudan

Introduction

High output heart failure is a rare clinical syndrome. Causes include chronic severe anaemia, arteriovenous fistulas, thyrotoxicosis and thamine deficiency (beriberi). In this article we present clinical, echocardiographic and radiological findings in a case of high output cardiac failure with predominant right heart failure manifestations due to posttraumatic femoral arteriovenous fistula.

Clinical summary

A 30 year old male with a history of gunshot injury to the groin around 20 years of age experienced palpitations, exertional dyspnoea, fatigue and lower limbs oedema for several months .Clinical examination revealed a large volume collapsing pulse at a rate of 86 BPM, wide pulse pressure (BP 140/40) raised jugular venous pressure with prominent V wave and cardiomegaly. Cardiac auscultation revealed a mid systolic flow murmur over the aortic and pulmonary areas and a pansystolic murmur over the tricuspied area .Abdominal and lower limbs examination revealed pulsatile hepatomagely ,moderate ascites and lower limbs oedema. A thrill felt over the right femoral artery and a continuous machinary murmur was heard in the same area. Electrocardiogram showed sinus rhythm, p pulmonale and inverted T waves in leades V1 ---- V3(fig 1) .Chest X – ray showed cardiomegly. Echocardiographic examination revealed normal size left ventricle with normal systolic function, hugely dilated right ventricle and right atrium, and dilated tricuspid valve annulus with morphologically normal tricuspid valve leaflets (fig 2). Colour Doppler revealed severe tricuspid regurgitation. Peak systolic tricuspid regurgitation velocity was2.6 m/sec. The inferior vena cava was dilated with dilated hepatic veins with systolic flow reversal. Calculated cardiac output was 10.8 L/mint. CT angiography demonstrated rapid filling of the right femoral vein during the arterial phase of the injection consistent with an extremely high flow arteriovenous fistula between this vessel and the femoral artery (fig3) .The patient was treated medically, initially with diuretics and was then subjected to surgery .The fistula was repaired with remission of all the symptoms and signs of cardiac failure. Follow up echocardiographic study demonstrated reduction of the size of the right ventricle and atrium as well as regression of tricuspid regurgitation (fig4).

Discussion

In patients with high output states the venous return is substantially increased. In case of arteriovenous fistula the systemic vascular resistant is significantly reduced .This leads to

compensatory increase in heart rate ,stroke volume and cardiac output .Increase in ventricular preload or end diastolic volume is associated with higher ventricular diastolic pressures and if

this rise in filling pressure is of sufficient magnitude symptoms and signs of congestive heart failure will occur.

High output state affects both ventricles. In this case the clinical examination displayed signs related to increased left ventricular stroke volume i.e. bounding pulse, wide pulse pressure and haemic murmurs. However symptoms, and signs of heart failure were predominantly right sided (dilatation of right heart chambers ,severe tricuspid regurgitation shown by Doppler echocardiography , P pulmonale and right ventricle strain by the ECG) This could be explained by the fact that the thin walled right ventricle gave way first or by the fact that the right heart chambers are the direct draining chambers of the fistula.

This has been observed by us before in a similar case where a patient with a congenital aortacaval fistula presented with predominant right heart failure and severe tricuspid regurgitation .

Isolated right heart failure has been reported in patients with severe thyrotoxicosis (1)

Acquired arteriovenous fistulas are usually posttraumatic or iatrogenic. Traumatic causes include bullet or knife wounds especially in the thigh (2) . Iatrogenic fistulas are surgically constructer arteriovenous fistulas used for access to the circulation in patients undergoing chronic haemodialysis (3/4). Arterial puncture for cardiac catheterization is an increasing common iatrogenic cause of arteriovenous fistulas. However high output failure is rare with an incidence of .01 to .02 % of all catheterizations .

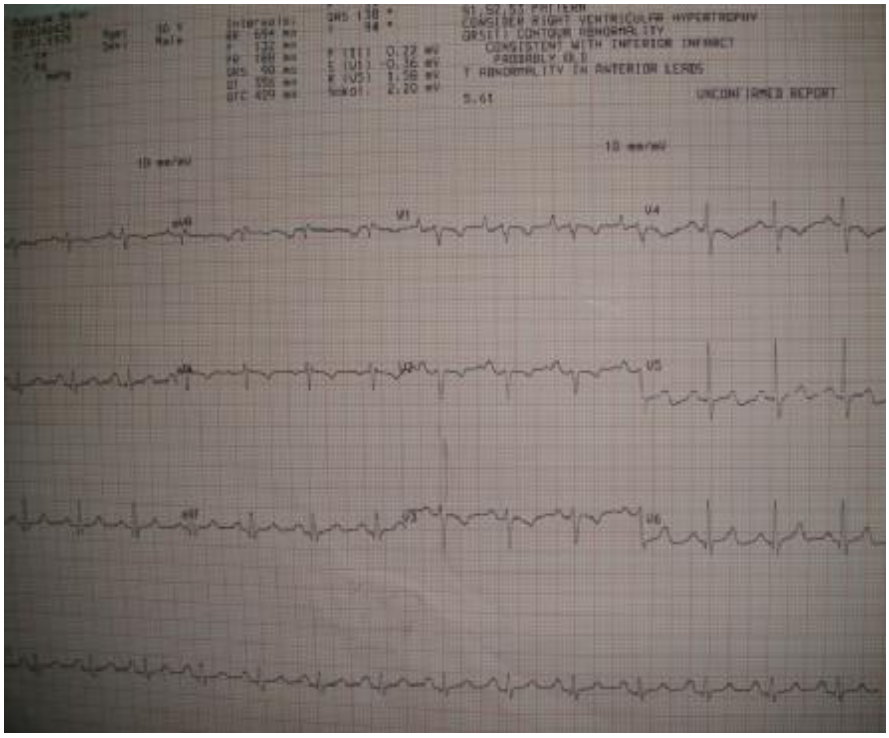

(Figure 1) Electrocardiogram Showing :
p pulmonale and inverted T waves in leades V1 ---- V3.



(Figure 2) Transthoracic echocardiography
4chamber view showing dilated right ventricle and right atrium.



(Figure 3) CT angiography showing :
rapid filling of the femoral vein during the arterial phase of the injection .

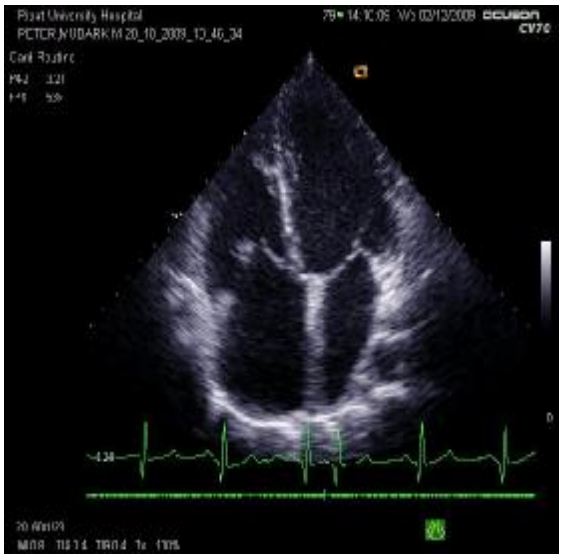

(Figure 4) Transthoracic-echocardiography showing : reduction in the size of the right heart chambers following repair of the fistula .

References

1. *Tam,VHK,Fung, LM Severe right heart failure in 2 patients with thyrotoxicosis .Hong Kong Med J 2008;14(4):321-3*

2. *Dorney, ER. Peripheral A.V fistula of fifty seven years duration with refractory heart failure .Am Heart J1957; 54:778.*

3. *Anderson, CB, Cod,JR,Graff.RA.etal,Cardiac Failure and upper extremity AV dialysis Fistula .Case reports and review of the literature .Arch Intern Med 1976 I 136:292.*

4. *Engelberts,I,Tordoir,JH,Boon,ES,Schreij,G.High output cardiac failure due to excessive shunting in a haemodialysis access fistula Am J Nephrol 1995;15:323.*