A giant thrombus inside a gigantic right Atrium, a case of right-sided Endomyocardial fibrosis

Dr Anas Babiker[1*], Dr Samahir Mutwali[2], Prof. Abdullah Abdelkareem[3]
[1,2]Alzaytouna Specialist Hospital, Khartoum, Sudan, [3]University of Gezira, Medani, Sudan
* Corresponding Author: Tel: +249912174391, Email: abumalik12@hotmail.com

A 29- year-old male patient was referred with an 8-months history of dyspnoea and abdominal distension which were getting worse in the last 2-months. Physical examination showed signs of right heart failure with large ascitis, hepatomegaly and minimal lower limb edema disproportionate to the degree of ascitis. A chest X-ray showed cardiomegaly. An echocardiographic examination revealed a hugely dilated right atrium, measuring 15-cm (panel A) with a large thrombus of 8 x 4-cm attached to the posterior wall of the right atrium (Panel B) with spontaneous echo contrast and another thrombus forming in the right atrium (Panel C).The tricuspid valve was difficult to see and almost completely destroyed (Panels D & E, white arrows).The right ventricle was rudimentary with obliteration of the right ventricular apex (Panels D& E black arrow). Large pericardial effusion noted (Panel F). The result of the physical examination and the echocardiographic findings were consistent with the diagnosis of right sided endomyocardial fibrosis, a common cause of restrictive cardiomyopathy in the tropics. The patient was started on anticoagulation and diuretics and scheduled for regular follow up.

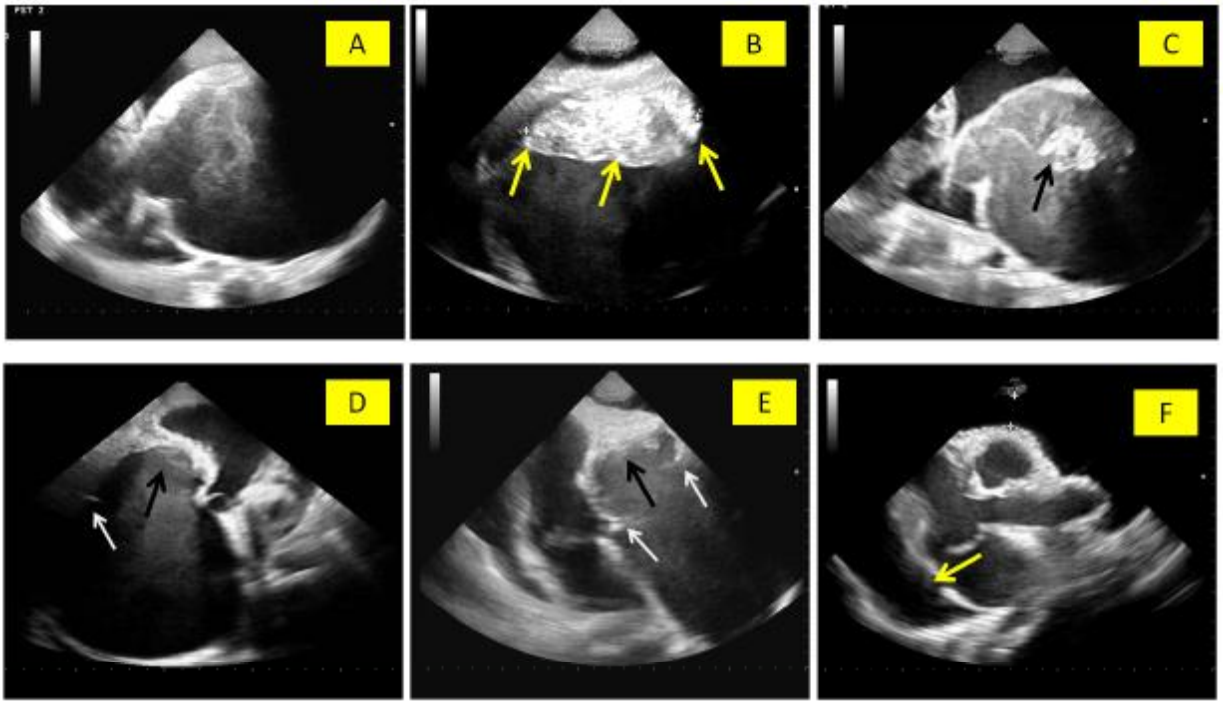
A
B
C
D
E
F