Holt Oram syndrome in a Sudanese patient

Saad Subahi *,Mohamad Marghani Osman **

*College Of Medicine,Al-Ribat University,Khartoum,Sudan

**College Of Medicine,Khartoum University,Khartoum,Sudan

Key Words:

Holt Oram, Sudanese patient

Case Report:

A 28 year old Sudanese female presented with shortness of breath on moderate exertion for several months,but no cough or chest pain. She had no past history or family history of relevance. She also denied any previous medical consultation.

Physical examination revealed obvious deformities affecting both hands *(Fig 1).* The left arm was noted to be shorter than the right with absence of thumbs in both hands. Vital signs were Normal. Pulse rate was 75/min, regular, BP 110/70,JVP was not raised.There was wide fixed splitting of S2 with soft systolic murmur in the pulmonary area. She had no signs of heart failure. Other systems were normal.

Routine blood tests and oxygen saturation at rest were normal.

ECG showed sinus rhythm with prominent P wave in lead II,incomplete right bundle branch block with normal PR interval.

Chest x-ray showed cardiomegaly with pulmonary plethora.

Transthoracic Doppler echocardiography showed dilated right ventricle, right atrium and pulmonary artery.There was a large (2.7 cm) secundum atrial septel defect and left to right shunt with normal Doppler derived systolic pulmonary artery pressure.

These cardiac abnormalities were confirmed by transoesophageal echocardiography .(*fig 2*)

The above findings are consistent with the diagnosis of Holt-Oram syndrome.

Discussion:

Holt-Oram syndrome(also known as the heart-hand syndrome) is characterized by fore limb deformities and congenital heart defects. It was first described in 1960 [1] and inherited as autosomal dominant manner. The clinical and genetic spectrum has been fully described [2]. Cardiac defects are common in this syndrome and are reported in 95 percent of cases. The commonest being atrial septal defects: single ,associated with ventricular septal defects or atrioventricular canal defects. Other types of congenital heart defects such as hypo plastic left heart syndrome,persistent left superior vena cava [3] and mitral valve prolapse have also been reported.

Conduction defects such as bradycardia, atrioventricular blocks, atrial fibrillation and sinus node dysfunction may occur.

Upper limbs are always involved in this syndrome. Abnormalities may be unilateral or bilateral and usually involve the radial, carpal and thenar bones.Triphalangeal or absent thumbs and upper extremity phecomelia may be present. Lower limbs defects are also known to occur [4].

Our patient exhibited the most common features of this syndrome, namely the mentioned limbs deformities together with the secundum atrial septal defect which is the commonest cardiac abnormality seen in this syndrome and is reported in 60 percent of cases.

The diagnosis of this syndrome is thus a clinical one. Other rare conditions present with limb and heart anomalies .Of this, the most well known is Fanconi anemia which is characterized by malformations of thumbs,forearms and heart with bone marrow failure.



Figure (1):The left arm was noted to be shorter than the right with absence of thumbs in both hands.

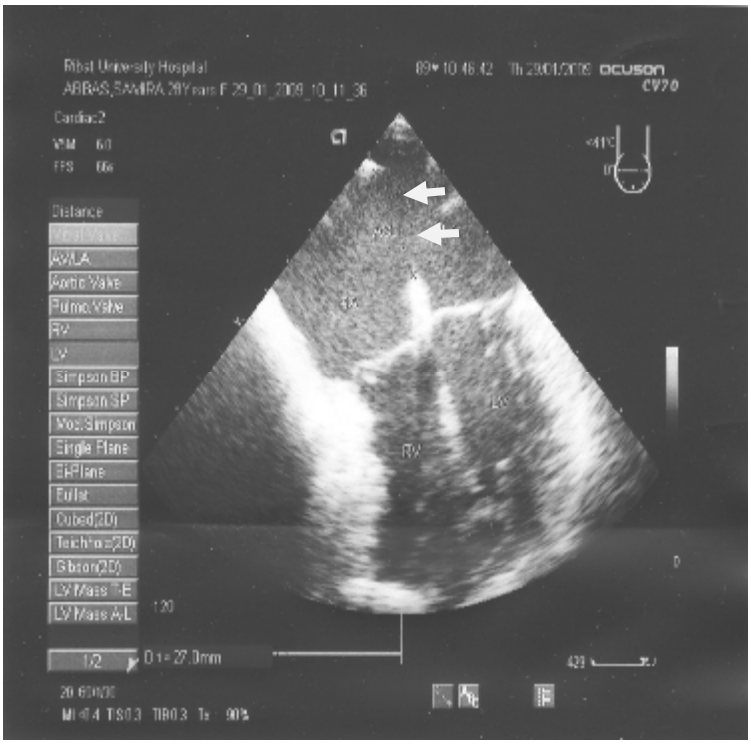

Figure(2): Transoesophageal echocardiogram showing large secundum atrial septal defect.(arrows)

References:

[1] Holt M, Oram S. Familial heart disease with skeletal malformations. Br Heart J 1960; 22: 236-42

[2] Basson CT, Cowley GS, Solomon SD, et al. The clinical and genetic spectrum of the Holt-Oram syndrome (heart-hand syndrome). *N Engl J Med*. Mar 31 1994;330(13):885-91. [Medline]. [Full Text].

[3] Cheng TO. Persistent left superior vena cava in Holt-Oram syndrome. *Int J Cardiol*. Oct 2000;76(1):83, 81-2. [Medline].

[4] Garavelli L, De Brasi D, Verri R, Guareschi E, Cariola F, Melis D, et al. Holt-Oram syndrome associated with anomalies of the feet. *Am J Med Genet A*. May 1 2008;146A(9):1185-9. [Medline].