Buddy Wire Technique In Percutanous Coronary Intervention

Elbagir Elbasheer, Isam Eltayeb, Mubarak Hassan, Shazally Musa

A 70 Year old male presented with acute inferior myocardial infarction and complete heart block. The still images are from his procedure.

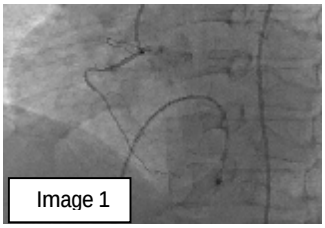

Image 1

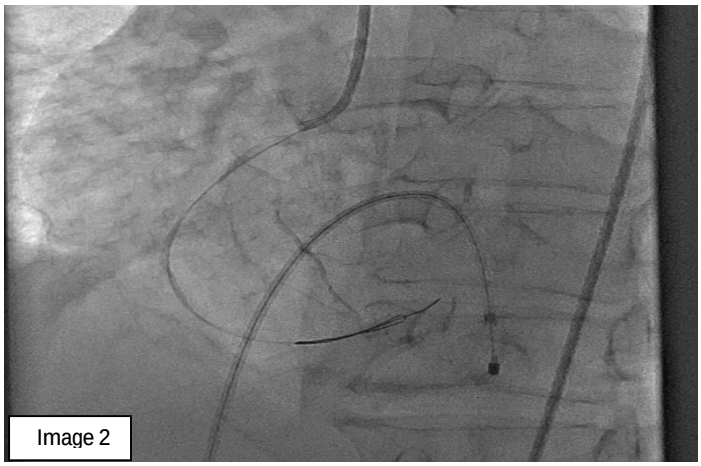

Image 2

Image 1 shows the totally occluded RCA with a temporary pacing wire to the RV apex. After multiple inflations with different size balloons it was not possible to cross the lesion with 2.5X22 mm stent. A Buddy wire is passed to the distal RCA(Image2). Stent passed successfully through the lesion and the buddy wire was removed immediately (make sure to remove the right wire!). Stent inflated(Image3) with and excellent final angiographic result and TIMI iii flow(Image 4).

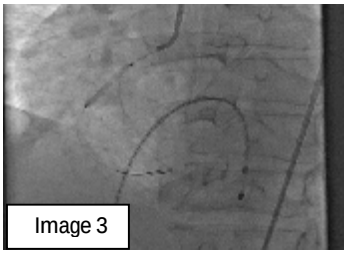

Image 3

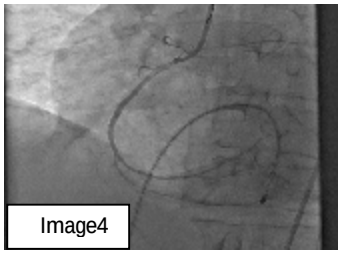

Image4

Discussion:

The Buddy wire technique is a simple trick which renders an otherwise difficult procedure into a simple peace of cake one. It spares time and effort and saves the operator the haste of replacing the whole hardware system and/or further traumatic balloon dilatation. The Buddy wire is meant to support the guiding catheter, further straighten the vessel and facilitate passage of the balloon/stent thorough the calcified and fibrotic lesions.