Occurrence of left ventricular thrombus post myocardial infarction causes significant morbidity and exerts management dilemma

Musa Anas*, Radaideh Ghazi**, Govindaswamy Pushparani***

*SpR cardiology Rashid Hospital – Dubai –UAE, ** Consultant cardiologist Rashid Hospital – Dubai –UAE, *** SR echocardiographer Rashid Hospital – Dubai –UAE

Summary:

62 year-old male who is known case of diabetes mellitus, on oral hypoglycaemic treatment; but not on regular follow up came to our emergency because of two days recurrent acute dyspnoeic episodes. He was diagnosed as pneumonia and started on antibiotics. However; his cardiac markers were rising and referred to our team who diagnosed him with late presentation anterior STEMI and pulmonary edema. He developed left ventricle thrombus (LVT) while on anticoagulation and embolized to his left-brain. He was managed by multidisciplinary team and discharged home with grade III+/V power right upper limb weakness.

Background:

Although rare in the era of aggressive anti-coagulation, thrombolytic therapy and percutaneous coronary intervention (PCI), LVT still developed in our patient with emboli to his brain causing significant disability. Starting anticoagulation in the presence of intracranial haemorrhage is a challenging decision. Dual antiplatelet therapy, in the setting of acute coronary syndrome, recommended continuing for one year putting in mind that the bleeding risk of dual antiplatelet with aspirin and clopidogrel is less than that of warfarin plus aspirin or clopidogrel, [1]. Lack of clear guidelines and complexity of complications alert use of integrated multidisciplinary approach in the management of similar cases.

Clinical case scenario:

A 62-year-old male a known case of type II diabetes mellitus on oral hypoglycaemic therapy, came to our emergency because he experienced two acute attacks of shortness of breath that started suddenly early morning over two days. He consulted primary health care physician who treated him with bronchodilators with some improvement as he found him wheezing. When he had the second attack, his primary care physician referred him to the hospital where he was found with right lower lobe consolidation. He was treated under respiratory care as he gave history of cough but slight fever if any. Then he was referred to our team because of electrocardiogram (ECG) abnormalities and rising cardiac troponins.

Further questioning did not reveal any history of chest pain, syncope, palpitations, sweating, dizziness, or even any previous hospitalization. No previous cardiac problems and no family history of dyslipidaemia or coronary artery disease. He is

Correspondence: Dr Anas M A Musa, anasy120@yahoo.com, Contact: 00971501193198.
Rashid hospital – Cardiology department, Dubai – UAE, P.O.Box 4545 AudMeitha

nonsmoker and does not consume alcohol.
His initial examination showed blood pressure of 139/80mmHg. Pulse rate was 120 beat/minute. Respiratory rate was 20 cycle/min, his temperature was 37 degrees C, and SO2 was 97% on room air. Heart sounds were normal with tachycardia and his chest examinations revealed scattered wheezes with bilateral basal crepitation more in the right lower chest. There are no lower extremities edema, and no focal neurological deficit.

Investigations:

White blood count 20.8 X10^3, hemoglobin was 14.4 g/dl and platelets count 205 X10^3. Cardiac pro-BNB: 170pg/ml that rose to 2526 pg/ml. Maximum creatinine Kinase (CK) is 631U/L and CKMB was 31 U/L. Troponins rose from 0.05 to 0.52ng/ml. The procalcitonin levels rose from 0.26 to 0.93ng/ml, but C reactive protein was negative and blood culture did not show growth after 3 days. Random blood glucose was 475mg/dl and hemoglobin A1C is 8.6%. The lipid profile showed total cholesterol of 184mg/dl, triglycerides of 113mg/dl, high density lipoprotein of 61mg/dl, and low density lipoprotein of 116mg/dl. Prothrombin time (PT) was 13.2 seconds, activated partial thromboplastin time (aPTT) was 27.8 seconds and international normalized ration (INR) was 1.03. His urea and electrolytes were normal as well as urine routine. His chest X-ray reported with right lower lobe consolidations that resolved rapidly after intravenous frusemide (figures 1 and 2).

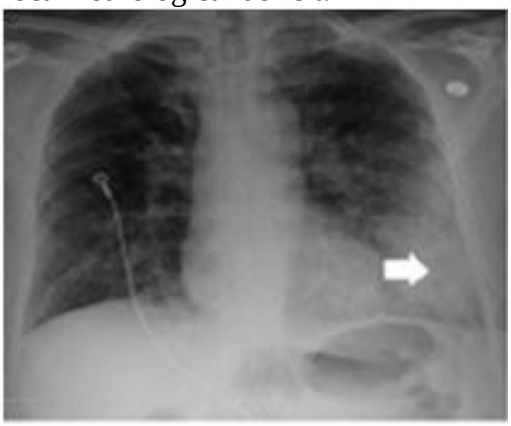

Fig 1: right lower lobe consolidation (white arrow)

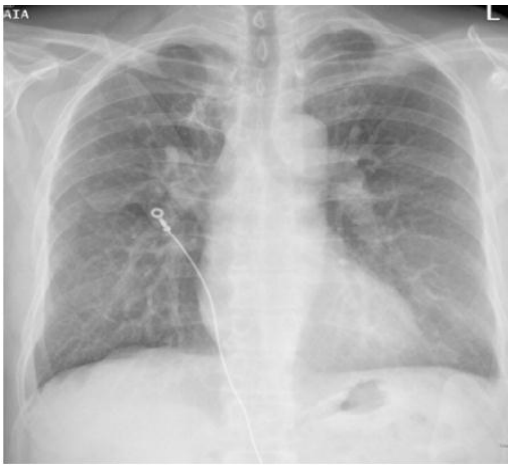

Fig 2: improving of consolidation in the right side immediately after frusemide suggestive of resolving pulmonary edema

The electrocardiogram showed ST elevations with Q waves in anterior leads and latter evolutional t-waves (figures 3 and 4).

Correspondence: Dr Anas M A Musa, anasy120@yahoo.com, Contact: 00971501193198.
Rashid hospital – Cardiology department, Dubai – UAE, P.O.Box 4545 AudMeitha

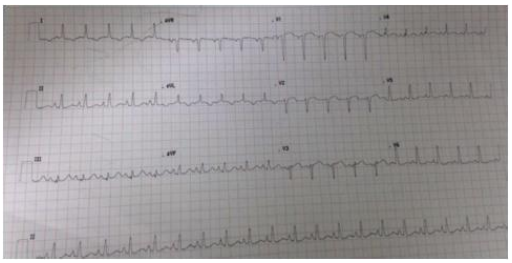

Fig 3: first ECG: sinus tachycardia, minimal ST elevation and Qs in V1-3, with T-inversion in leads I, aVL

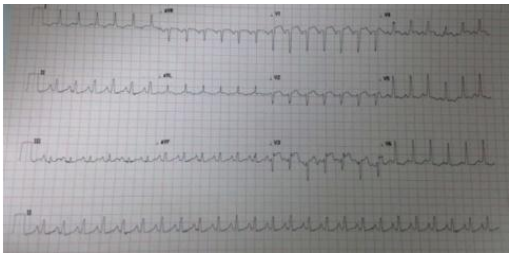

Fig 4: follow ECG shows more clear changes as in figure 3 above

Echocardiography showed regional wall motion abnormality in anterior and lateral wall. Severely impaired left ventricular systolic function with ejection fraction of 15 - 20%. Grade 2/4 mitral regurgitation and type 2 diastolic dysfunction.

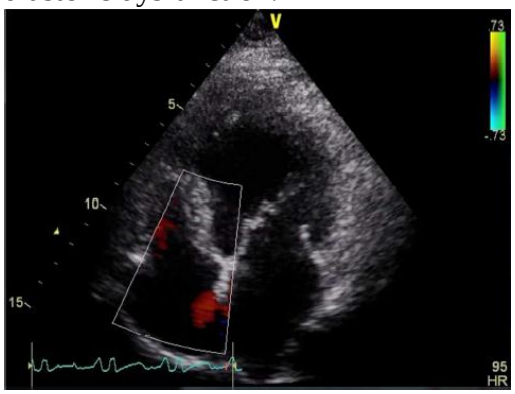

Fig 5: Initial echo upon admission showed left ventricular dysfunction with RWMA, no apparent LV clot

Treatment and inpatient course:

The patient care was transferred to cardiology and he was started on anticoagulation with enoxaparin 1mg/Kg twice a day, dual antiplatelet (aspirin 100mg and clopidogrel 75mg), and atorvastatin 80mg daily. He also received diuretics, continued on antibiotics, started on spironolactone, angiotensin converting enzyme inhibitor, beta-blocker, and continued on insulin. He improved a lot and planned for coronary angiography as outpatient according to his preference. On the day before discharge, he suffered right side weakness associated with slurred speech and lost sphencteric urge, but no other cranial nerves signs. Initial brain CT scan was normal; but with big right middle cerebral artery infarcts and hemorrhagic transformation in the follow up scanning (figures 6, 7).



Fig 6: initial brain CT without evidence of infarction

Correspondence: Dr Anas M A Musa, anasy120@yahoo.com, Contact: 00971501193198.
Rashid hospital – Cardiology department, Dubai – UAE, P.O.Box 4545 AudMeitha



Fig 7: follow up brain CT showed large right mid cerebral artery infarction with hemorrhagic transformation (black arrows)

He was treated conservatively by neurologist and started on physiotherapy with bladder training. His enoxaparin and clopidogrel were stopped and continued on Aspirin. Follow up echocardiography showed small mobile intertrabuclar LV clot that was not there before his stroke in the first echo report (figures 5, 8).



Fig 6: follow up echo showed left ventricular apical clot (white arrows)

Upon discharge, the patient was fully conscious and oriented, with grade III+/V power right upper limb weakness, his speech normalized and improved grade IV+/V power in his right leg. During follow up visits, he does not have any complains and his power improved a lot. His repeat echocardiography did not show any clot. The decision was made to continue on aspirin and clopidogrel for one year in view of recent bleeding, disappearance of the LVT, and the presence of acute coronary syndrome (ACS).

Discussion:

Patients with left ventricle thrombus (LVT) present difficulty and management dilemma, [2]. Although management of acute myocardial infarction improved much especially in the era of thrombolytic therapy and PCI; still this type of management cannot apply to all patients admitted.

The frequency of LVT is variable with range from 7 – 46% as reported in the literature, [3]. In one analysis of left ventricular aneurysm after surgery found that LV thrombus is present in 50% of cases,[4] Anticoagulation is proven therapy to reduce incidence of formation of LV clot and in a follow up cases of LV clot,[5] found no clot after 3month.

Despite full anticoagulation and antiplatelet therapy, our patient developed LVT. It is clear in this case that due to the patient presented late to the hospital and initial presumable diagnosis of pneumonia contribute to the delay of receiving the proper timely management and increased his risk in developing left ventricular clot.

Many risk factors identified for developing left ventricular clot in the setting of acute myocardial infarction. For example, poor left ventricular function and ST elevation myocardial

Correspondence: Dr Anas M A Musa, anasy120@yahoo.com, Contact: 00971501193198.
Rashid hospital – Cardiology department, Dubai – UAE, P.O.Box 4545 AudMeitha

infarction type as present in this patient, and many others including and not limited to,[6] large infarcts area, apical dyskinesia, and anterior myocardial infarction.

The echocardiography is central in detecting the presence of LVT post myocardial infarction, [7]. However; it is sensitivity and specificity is 90%, [8]. Jonathon W et al, [9] concluded that routine echocardiography with rare contrast can yield misleading results concerning presence of LVT. The echocardiography detection can be enhanced by using contrast type of study, [10] that possess high specificity and sensitivity and it can be used to facilitate, [11] anatomical and tissue characterization approaches for thrombus detection. Many other modalities are used to enhance diagnosis of LVT like cardiac MRI that can better detect small thrombi with better results especially if it is contrast enhanced, [12].

Once LVT occurred, there is increased risk of embolization that was maximum during early weeks after myocardial infarction but this risk is reported up to beyond 3 months that is responsible for 15% of ischemic stroke, [13]. This risk increased with age and type of LVT especially if the thrombus is large, protruding, and mobile, [11].

Our patient developed cerebral infarction that transformed into hemorrhagic infarcts a peculiar characteristic of LVT related cerebral infarcts, [2] which carries potential risk for hemorrhagic transformation as same as recurrent embolic risk.

Multidisciplinary approach is the usual management of patients with myocardial infarction, stroke, and left ventricular clot. Continuation of anticoagulation in such types of patients with recent myocardial infarction and hemorrhagic stroke is difficult decision. Because of lack of clear guidelines regarding anticoagulation in this particular case, we preferred to defer the decision till latter review with echocardiography in the clinic after two weeks.

The patient was seen and repeat echo did not show any LVT although now neurologically fit for anticoagulation. There are no fixed recommendations regarding duration of anticoagulation after development of LVT in the setting of ACS. While European cardiology guidelines in this setting recommend up to 6 months of oral anticoagulation, however; they opted that it can be lessened if repeated echocardiography shows disappearance of the clot and improvement of ventricular wall movement in 3 months' time, [14].

Albert and his colleagues, [15] reported 93% resolution of LVT after anticoagulation in follow up echocardiography. Nevertheless, we could not continue anticoagulation on our patient because of hemorrhage. By the time of discharge within 3 weeks of admission, we were able to discharge him on dual antiplatelet therapy with Aspirin and clopidogrel with no further complications during follow up visits.

Conclusion:

LVT is very difficult to treat in patients with cerebral infarcts and hemorrhagic transformation and leads to significant morbidity and disability. It needs

Correspondence: Dr Anas M A Musa, anasy120@yahoo.com, Contact: 00971501193198.
Rashid hospital – Cardiology department, Dubai – UAE, P.O.Box 4545 AudMeitha

careful assessments of risks and involvement of patient in the active care with multi-disciplinary approaches with physiotherapist, neurologist and cardiologist especially after acute myocardial infarction and proposed cardiac intervention therapy. Bleeding and embolic risk should be carefully assessed and decision can be made on these bases. Lack of clear guidelines and complicated course necessitates multidisciplinary inputs from different departments involved into patient's care to formulate the management plan.

Take home message from this case:

1- Despite improvement of management and early diagnosis of acute coronary syndromes still some patients can be missed and develop complications specially if their presentation is atypical
2- Left ventricular clot detection can be enhanced using contrast echo study but this modality is not widely used including my organization.
3- Patient with severe LV dysfunction should be carefully evaluated for presence of LVT on admission and before discharge a practice that should be adopted and encouraged in every day clinical practice
4- LVT, myocardial infarction and stroke is a triad difficult to manage and needs multidisciplinary care putting in considerations patient status and preference

References:

1. Morten L. Hansen, MD, PhD; Rikke Sørensen, MD; Mette T. Clausen, MSc Pharm; Marie Louise Fog-Petersen, MSc Pharm; Jakob Raunsø, MD; Niels Gadsbøll, MD, DMSc; Gunnar H. Gislason, MD, PhD; Fredrik Folke, MD; Søren S. Andersen, MD; Tina K. Schramm, MD; Steen Z. Abildstrøm, MD, PhD; Henrik E. Poulsen, MD, DMSc; Lars Køber, MD, DMSc; Christian Torp-Pedersen, MD, DMSc: Risk of Bleeding With Single, Dual, or Triple Therapy With Warfarin, Aspirin, and Clopidogrel in Patients With Atrial Fibrillation, Arch Intern Med. 2010;170(16):1433-1441.

2. Khalil Al-Farsi, Aftab A. Siddiqui, Yasser W. Sharef, Ali K. Al-Belushi, Hakeem Al- Hashim, Mohammed Al-Ghailani, and William J Johnston: Hemorrhagic Cardioembolic Stroke Secondary to a Left Ventricular Thrombus: a Therapeutic Dilemma. Oman Med J. 2013 Jan; 28(1): 56–59.

3. Peter J. Stokman, MD, Charn S. Nandra, MD, MB, BCh (Wales), Richard W. Asinger, MD: Left Ventricular Thrombus; Current Treatment Options in Cardiovascular Medicine 2001, 3:515–521

4. Ellenc .K Feley, M.D., And L. Davdh Illism, .D: Left Ventricular Mural Thrombus after Acute Myocardial Infarction; Clin. Cardiol. 19, 83-86 (1996)

5. CR Potu , EE Tulloch-Reid, DS Baugh, EC Madu: Left ventricular thrombus in patients with acute myocardial infarction: Case report and Caribbean focused update; Australasian Medical Journal 2012, 5, 3, 178-183

Correspondence: Dr Anas M A Musa, anasy120@yahoo.com, Contact: 00971501193198.
Rashid hospital – Cardiology department, Dubai – UAE, P.O.Box 4545 AudMeitha

6. Ertuğrul Okuyan, Barıs Okcun, Mustafa H Dinçkal, Hasim Mutlu: Risk factors for development of left ventricular thrombus after first acute anterior myocardial infarction-association with anticardiolipin antibodies; Thrombosis Journal 2010, 8:15

7. Mauro Pepi, Arturo Evangelista, Petros Nihoyannopoulos, Frank A. Flachskamp, George Athanassopoulos, Paolo Colonna, Gilbert Habib, E. Bernd Ringelstein, Rosa Sicari, and Jose Luis Zamorano on behalf of the European Association of Echocardiography: Recommendations for echocardiography use in the diagnosis and management of cardiac sources of embolism; European Journal of Echocardiography (2010) 11, 461–476

8. J. M. van Dantzig, B. J. Delemarre, H. Bot and C. A. Visser: Left ventricular thrombus in acute myocardial infarction; European Heart Journal (1996) 17, 1640-1645

9. Jonathan W. Weinsaft, MD, Han W. Kim, MD, Anna Lisa Crowley, MD, Igor Klem, MD, Chetan Shenoy, MD, Lowie Van Assche, MD, Rhoda Brosnan, MD,Dipan J. Shah, MD, Eric J. Velazquez, MD, Michele Parker, RN, MS, Robert M. Judd, PHD, Raymond J. Kim, MD: LV Thrombus Detection by Routine Echocardiography Insights Into Performance Characteristics Using Delayed Enhancement CMR; J A C C : cardiovascular imaging Vol . 4, no . 7, 2011, 703 – 712

10. N Reichek, J Helak, T Plappert, M S Sutton and K T Weber: Anatomic validation of left ventricular mass estimates from clinical two-dimensional echocardiography: initial results. Circulation. 1983;67:348-352

11. Jason S Chinitz, MD, Dorinna D Mendoza, MD, Raymond J Kim, MD and Jonathan W Weinsaft, MD.: Cardiac Imaging for Assessment of Left Ventricular Thrombus; US Cardiology, 2009;6(2):27-33

12. Frank A. Flachskampf , Michael Schmid, Christian Rost, Stephan Achenbach, Anthony N. DeMaria, and Werner G. Daniel: Cardiac imaging after myocardial infarction. European Heart Journal (2011) 32, 272–283

13. Ronak Delewi, Felix Zijlstra, Jan J Piek: Left ventricular thrombus formation after acute myocardial infarction; Heart 2012;98:1743–1749. doi:10.1136/heartjnl-2012-301962

14. Hein Heidbuchel, Peter Verhamme, MarcoAlings, Matthias Antz,WernerHacke, Jonas Oldgren, Peter Sinnaeve, A. John Camm, and Paulus Kirchhof: EHRA Practical Guide on the use of new oral anticoagulants in patients with non-valvular atrial fibrillation: executive summary. Europace (2013) 15, 625–651

15. Albert J. Funke Kupper, MD, Freek W.A. Verheugt, MD, FACC, Cathinka H. Peels, MD, Tjebbe W. Galema, MD, Jan P. Roos, MD: Left Ventricular Thrombus Incidence and Behavior Studied by Serial Two-Dimensional Echocardiography in Acute Anterior Myocardial Infarction: Left Ventricular Wall Motion, Systemic Embolism and Oral Anticoagulation; JACC Vol. 13, No. 7 June 19891: 51 4-20

Correspondence: Dr Anas M A Musa, anasy120@yahoo.com, Contact: 00971501193198.
Rashid hospital – Cardiology department, Dubai – UAE, P.O.Box 4545 AudMeitha