Bees' sting, different mechanisms for Myocardial Infarction

Anas B. Babiker, M.D.[1] , Hamoda A. Ali, M.D. [2], Elbagir Elbasheer, M.D.[3] .

Key words: *Bee sting, Acute myocardial infarction*

1.consultant interventional cardiologist, FESC, MRCP, Royal care international hospital
2. Cardiology Fellow, Sudan Heart Centre.
3. Consultant interventional cardiologist, Sudan Heart Centre

Introduction:

Insect bites and stings, especially bee stings, are a common encounter especially in rural areas. These stings are frequently associated with allergic reactions which may prove to be fatal at times. Cardiovascular effects of these stings are not well addressed in the literature. In this case report we will discuss two patients with bee sting resulting in acute myocardial infarction:

CASE I

A 69 years male, who is previously healthy with no history of DM or hypertension who was cutting the trees in his garden and incidentally he hit a beehive that resulted in around 10 bees' stings. Few minutes later he started to have severe crushing central chest pain that radiates to his jaw and associated with drenching sweating. He presented to ER 2 hours later, his HR was 110 bpm, BP 160/100, cardiovascular and chest examinations were unremarkable. His ECG showed ST elevation in in the inferior leads (2mm) with posterior extension (Fig. 1). The Patient was thrombolysed with streptokinase with immediate response and ST elevation resolution of more than 50% with complete resolution of chest pain. Peak Troponin T was 4.76. His fasting lipids and fasting blood glucose were both within normal limits. His renal profile and full blood count were both normal. 36 hours later, underwent coronary angiography that showed a large thrombus in proximal RCA with no significant stenosis and multiple thrombi filling the distal right coronary artery and occluding a small branch of posterolateral branch (PLB) of the RCA (Fig 2). No stenting was needed and the patient was treated with GII P III A inhibitors (tirofiban) in combination with enoxaparin, Aspirin and Clopidogrel with more resolution of his ST elevation, echocardiography was normal. Patient discharged on day 4 in excellent condition

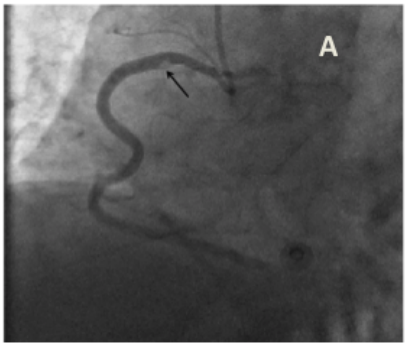
A

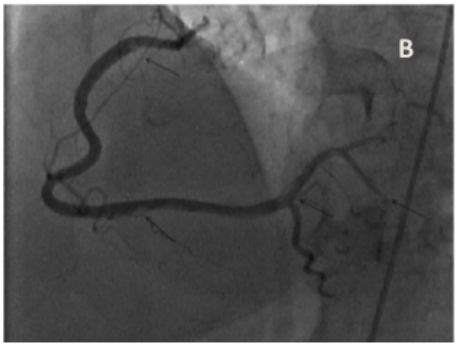
B

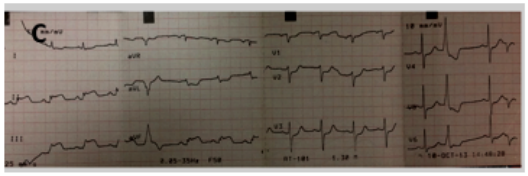

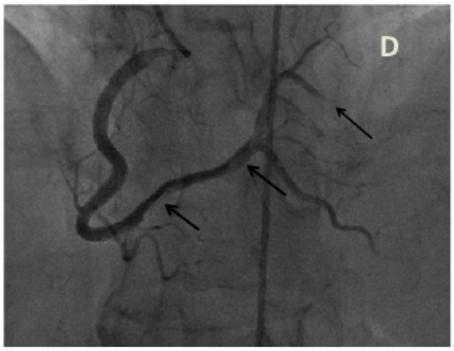
D

CASE II

A 60 years old male farmer with no significant background history and on no regular medications, sustained multiple bees' stings while working in his farm, few minutes later he developed severe central crushing chest pain associated with nausea & vomiting .he sought medical advice in the regional hospital, where he was diagnosed as ACS. Examination was unremarkable apart from sinus tachycardia, his ECG showed ST elevation in inferior leads. His cardiac Troponin T was positive. CXR normal. He was thrombolysed with resolution of inferior ST elevation. Referred to the Capital for further management. His echocardiography showed Apical and inferior akinesis, EF 35% with apical thrombus, and secondary moderate mitral regurgitaion. His coronary angiography showed LAD: small vessel with diffuse disease .D1 ostial tight disease. LCX: normal. RCA: mid 80% disease not relieved by nitrate (fig E) . Direct stenting with 2.75x15mm drug-eluting stent was done with good results[Fig F].



[Fig E]



[Fig F]

.

Discussion

Apitoxin or honey bee venom is a bitter colourless liquie[1]; its active portion a mixture of proteins which can cause local inflammation and results in serious systemic reponse. The main component of the venom is melittin; Apamin increases cortisol production in the adrenal gland and it is a mild neurotoxic; Adolapin acts as anti-inflammatory and analgesic as it blocks cyclooxygenase; Phospholipase A2 degrades phospholipids which cellular membranes are made of and it causes hypotension and inhibits blood coagulation and it also activates arachidonic acid which is metabolized to form prostaglandins; Hyaluronidase dilates the capillaries causing the spread of inflammation; Histamine involved in the allergic response; Dopamine and noradrenaline increasing the pulse rate; Protease inhibitors act as anti-inflammatory and stop bleeding

The two cases have a similar scenarios that the ST segment elevation myocardial infarction was triggered by bees' stings but the mechanism of the infarction was different. In the first case the mechanism was extensive thrombosis possibly due to the thrombogenic effect of the bees venomor as a result of severe coronary spasm and platelet activation with no clear evidence of atherosclerosis that might have result from severe coronary spasm and possibly platelet aggregation while in the the second case the artery is atherosclerotic and the bees' venom triggered plaque rupture likely due to adrenergic surge. From the above two cases bees' sting which is commonly encountered especially in rural areas can result in severe cardiogenic complications by stimulation of different pathways that still needed to be study in details.

References:

1. Czarnetzki, B.M.;Thiele, T.; Rosenbach, T. (Feb 1990) (Evidence for leukotrienes an animal venoms). The Journal of allergy and clinical immunology 85 (2): 505-509.