REVIEW ARTICLE

Primary PCI for ST Elevation Myocardial Infarction with Heavy Thrombus Burden

Salaheldin Abusin, MD, MRCP, FACP, FACC. Interventional Cardiologist. Grand River Medical Group. Dubuque, IA, USA. Email: saybusin@hotmail.com

Objectives:

1. Case Study demonstrating the successful utilization of Mechanical thrombectomy device as a bailout in a case of Primary Percutaneous Coronary Intervention (PPCI) for ST Elevation Myocardial Infarction (STEMI) with Heavy Thrombus Burden
2. Review of the Evidence for the role of Manual Aspiration in PPCI for STEMI
3. Review of the Evidence for the role of mechanical thrombectomy in PPCI for STEMI

Case Presentation

A 72-year-old female presented with Inferior STEMI. She was taken emergently to the Cardiac Catheterization Laboratory for PPCI. Aspirin 325mg and Clopidogrel 600mg were administered orally in the Emergency Room, Intravenous Bivalirudin infusion was administered after obtaining vascular access.

Diagnostic Coronary Angiography revealed subtotal occlusion of the mid Right Coronary Artery (mRCA) with TIMI 1 Flow and Heavy, TIMI Grade 4, thrombus burden (Figure 1 Panel A). After advancing a 0.014”” Prowater â (Abbott Vascular) coronary guidewire across the lesion, a Pronto â (Vascular Solutions) manual aspiration thrombectomy catheter was advanced across the lesion (Figure 1 Panel B), and a small amount of thrombus was aspirated. Coronary Angiography (Figure 1 Panel C) demonstrated persistent TIMI Grade 4 thrombus in mRCA and distal embolization leading to complete occlusion of a large Right Posterior Descending Artery (RPDA).

After temporary right ventricular pacing, mechanical thrombectomy was performed with Angiojet â (Boston Scientific) (Figure 1 Panel D). Subsequent coronary angiography (Figure 2 Panel A) revealed significant reduction in thrombus burden and improved flow in the RPDA. Balloon Angioplasty with 3.0x18mm compliant balloon was performed followed by PCI with a 4.0x22mm Bare Metal Integrity â Stent (Medtronic) (Figure 2 Panel B). This was then post dilated with a 4.0 non-compliant balloon to 16 ATM. Final Angiography (Figure 2 Panel C) revealed an acceptable angiographic result with restoration of TIMI 3 flow in the RPDA, there was distal embolization in the Right Posterolateral segment (RPLS). The patient was maintained on Abciximab for 12 hours post PCI.

She made an uneventful recovery during the remainder of her hospitalization, with normal left ventricular systolic function and an estimated left ventricular ejection fraction of 55-60%; she remained without coronary events at one year follow up.

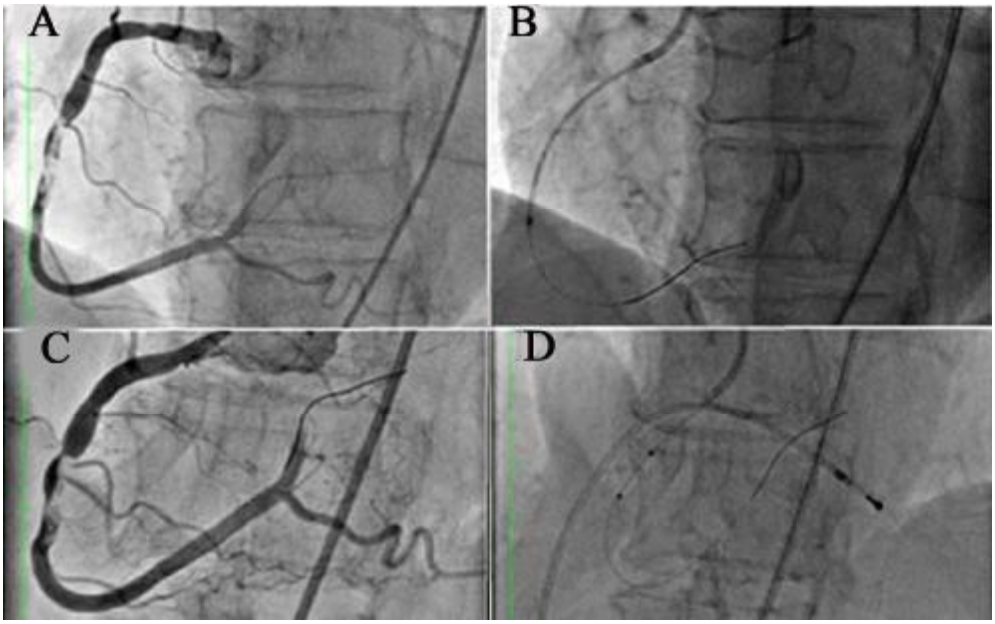

Figure 1. Panel A: Diagnostic Coronary Angiography revealing TIMI Grade 4 thrombus in mRCA. Panel B: Manual Aspiration Thrombectomy micro-catheter advanced across the lesion. Panel C: Persistent TIMI Grade 4 thrombus in mRCA with distal embolization to RPDA. Panel D: AngioJet Mechanical Thrombectomy Catheter advanced to mRCA, temporary pacing wire in-situ

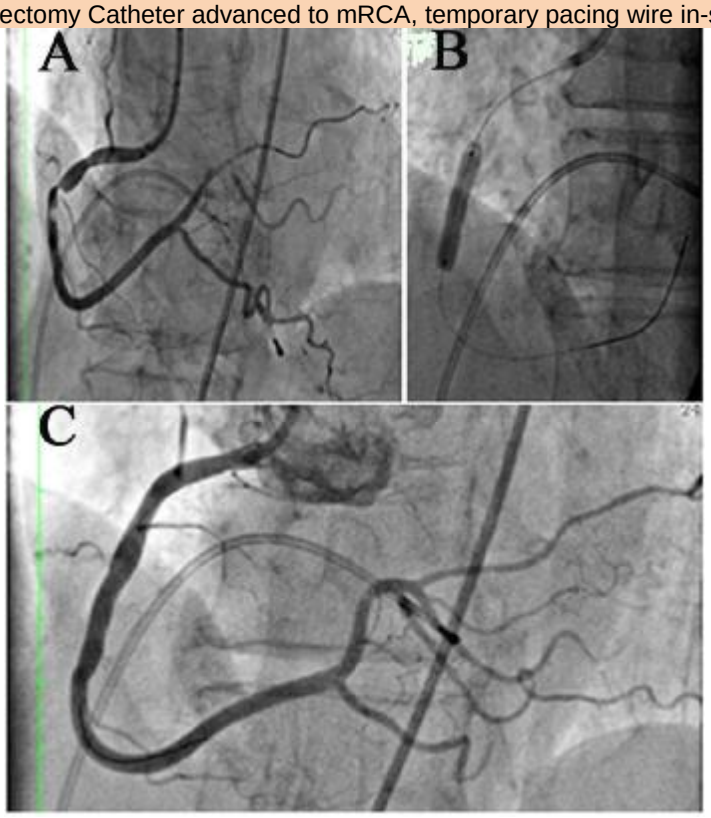

Figure 2. Panel A: Improvement in thrombus burden with restoration of diminished flow in RPDA. Panel B: PCI with 4.0x22mm Bare Integrity Metal Stent. Panel C: Final Angiographic result with restoration of flow in RPDA, residual thrombus in RPLS.

Introduction

The presence of coronary thrombus is a not infrequently encountered finding in patients with coronary artery disease. Early experience with coronary angiography in the 1980s reported the finding of coronary thrombus to be more associated with acute coronary syndrome compared to stable angina (83-100% compared to 0-17%) (1, 2).

It was seen in 45% of all-comers with non ST Elevation Acute Coronary Syndrome (NSTE-ACS) enrolled in the PRISM-PLUS clinical trial in 1999 & was associated with 2.4-fold increase in the odds of death at 30 days, and a 2-fold increase in the odds of myocardial infarction (3).

With the advent of PPCI for STEMI, more recent studies reported an incidence of 92% of coronary thrombus in patients with STEMI, with large thrombus burden in 32% of patients (4).

Important Definitions: TIMI flow Classification, Myocardial blush, TIMI Thrombus Grading

Table 1. TIMI Flow Grade Classification(5)

TIMI Flow Grade	Detailed Description	Detailed Description
0	No perfusion	No antegrade flow beyond the point of occlusion
1	Penetration without perfusion	Faint antegrade coronary flow beyond the occlusion with incomplete filling of the distal coronary bed
2	Partial perfusion	Delayed or sluggish antegrade flow with complete filling of the distal territory
3	Complete perfusion	Normal flow with complete filling of the distal territory

Table 2 Myocardial Blush Grading

Grade	Description
0	No blush
1	Minimal blush
2	Moderate blush
3	Normal blush

Myocardial Blush is an angiographic measure of myocardial perfusion. It assesses the reperfusion of the infarcted area of the myocardium independent of the blood flow in the epicardial coronary artery. It is graded based on the study by Van't Hoft et al. Myocardial blush grade is an independent predictor of mortality. (6)

Thrombus Grading (Table 3)

Table 3 .TIMI thrombus grading system

Thrombus	TIMI thrombus Grade	Detailed Description
No thrombus	0	
Possible thrombus	1	Angiography characteristics as reduced contrast density, haziness, irregular lesion contour, or a smooth convex “meniscus” at the site of total occlusion suggestive but not diagnostic of thrombus
Definite thrombus	2	Greatest dimensions <=1/2 the vessel diameter
	3	Greatest linear dimension >1/2 but <2 vessel diameters
	4	Largest dimension >2 vessel diameters
	5	Total occlusion

The TIMI thrombus grading system is the most widely used (7). Other classifications have been reported in the literature. (8)

Complications associated with coronary thrombus

Coronary thrombus leads to complications either by embolization or microvascular obstruction. Embolization can cause occlusion of either the proximal (propagation of thrombus to the left main in case of Left Anterior Descending (LAD) or Left Circumflex lesions) or distal vasculature (as shown in the case above). Embolization can occur in up to 15.2% of patients who undergo PPCI for STEMI as reported by Henriques et al. It has been associated with reduced angiographic success (with angiographic success defined as TIMI 3 flow with less than 50% residual stenosis), reduced myocardial blush, reduced ST segment resolution, larger enzymatic infarct size. More importantly, it was associated with lower ejection fraction at discharge, and higher mortality at a mean follow up of 5 years (9).

Micro-vascular obstruction leads to Slow or No Reflow which is defined as the reduction or cessation of coronary blood flow despite a patent vessel in the absence of dissection, visible thrombus, or spasm; or it may cause abnormal perfusion in spite of TIMI 3 flow**;** this phenomenon is well described and is associated with higher mortality (10)

Manual Aspiration Thrombectomy

This is achieved using rapid exchange microcatheters that manually aspirate thrombus. There are several types commercially available (e.g. Export â , Pronto â , Fetch â) which are generally similar, relatively easy to use, and inexpensive. There have been several studies that examined the use of these devices in patients with STEMI with mixed results. The TAPAS clinical trial published in 2008 demonstrated a significant improvement in myocardial blush, resolution of ST segment elevation in patients who underwent manual aspiration thrombectomy compared to those who did not, with a trend towards reduction of mortality at 30 days (11). The one year follow up

data demonstrated a significant reduction in mortality at one year (12). Similar findings were observed in the EXPIRA trial (13). A metanalysis of 9 clinical trials by De Luca et al demonstrated a significant reduction in 30 day mortality in patients with STEMI who underwent manual aspiration thrombectomy (14). Similar results were reported by a metanalysis of 11 clinical trials demonstrating a significant reduction in mortality and major adverse cardiovascular events (15). These results were reflected in both the European Society of Cardiology (ESC)'s 2012 STEMI guidelines & the American College of Cardiology (ACC)/American Heart Association (AHA) 2013 guidelines that gave the use of manual aspiration thrombectomy in patients with STEMI undergoing PPCI a Class IIa recommendation (should be considered) with level of evidence B (16) [i] (17). Interestingly, in spite of the evidence in favor of manual aspiration thrombectomy at the time, surveys of interventional cardiologists showed a gross underutilization of this technique with only 36% of respondents in one survey using it routinely, and 60% selectively; perhaps driven by personal experiences with complications associated with the use of the technique. (18, 19)

However, subsequent clinical trials yielded different results. The first was the INFUSE-AMI trial which showed no benefit with manual aspiration thrombectomy in patients presenting with proximal or mid LAD STEMI. (20) The Swedish TASTE clinical trial enrolled all-comers with STEMI (55.9% had Grade 3 or higher thrombus burden) and also showed no difference in clinical outcomes with routine manual aspiration thrombectomy (21). The Canadian TOTAL clinical trial (>90% had Grade 3 thrombus or higher) showed not only no benefit with routine manual aspiration thrombectomy but a higher stroke rate at 30 days (22). Based on this new evidence, the ACC/AHA updated its' STEMI guidelines to give routine manual aspiration thrombectomy a Class III recommendation (harm), with emphasis on the word "routine"; and Class IIb recommendation (may be considered) for the selective/bailout use of manual aspiration in patients undergoing PPCI for STEMI (23). The European guidelines were milder in their recommendation with a Class IIb recommendation for manual aspiration thrombectomy and no Class III recommendation for routine manual aspiration thrombectomy. (24)

Mechanical Thrombectomy (AngioJet â) System

This system uses high pressure saline to create a vacuum at the tip of the catheter to break up and remove thrombus. It is composed of a drive unit console, disposable pump set, and a disposable micro-catheter. The micro-catheter is advanced 1cm proximal to the thrombus and the system is activated, saline jets travel backwards from the tip of the catheter creating a vacuum effect, the thrombus is drawn into the catheter and the jet pushes the thrombus down the catheter. Recent improvements in the system made it more user-friendly and can now use a rapid exchange, 6F delivery platform. The main complication associated with AngioJet is transient, hemodynamically significant bradyarrhythmias; hence, the manufacturer recommends placement of a temporary pacing wire(25). The AiMi

trial studied AngioJet in patients undergoing PPCI for STEMI, without requiring the presence of visible thrombus on angiography. It demonstrated higher mortality and Major Adverse Cardiac Events (MACE) in patients who received AngioJet â **.** The main criticism of this trial was that only 6-10% of patients had large thrombus (26). The JETSTENT clinical trial recruited STEMI patients undergoing PPCI with large thrombus burden and at least 2.5mm diameter vessel. The trial showed lower MACE events at 6 months, and higher 1-year survival rates in patients who underwent AngioJet; however, it was considered a negative trial since it did not meet the primary endpoints of early ST segment resolution and (99m) Tc-sestamibi infarct size set by the investigators (27).

In 2008, Bavry et al compared the two modalities (Manual Aspiration Thrombectomy vs. Mechanical Thrombectomy) in a metanalysis that included 30 studies and concluded that manual aspiration thrombectomy was beneficial in mortality reduction while mechanical thrombectomy appeared to increase mortality(28). The same group of authors published an updated metanalysis to incorporate new evidence in 2013 with the same conclusion(29).

Comment

The conflicting evidence for the utilization of manual aspiration thrombectomy or mechanical thrombectomy stresses the importance of individualizing the use of these techniques to the findings on coronary angiography. The objective of successful PPCI is not only to establish brisk coronary flow and relieve the stenosis but also establish normal myocardial perfusion as measured by myocardial blush. Both of these objectives (restoration of flow and perfusion) are reduced in patients with high thrombus burden. Patients with no, possible or small thrombus would probably achieve that objective without the need for aspiration thrombectomy and definitely not mechanical thrombectomy. Those with heavy thrombus burden will probably need to undergo at least manual aspiration thrombectomy to achieve the above objective; and in rare circumstances (as the case illustrated) mechanical thrombectomy with AngioJet.

Take home Points

- Routine Manual Aspiration thrombectomy is no longer indicated for PPCI for STEMI.
- Selective Manual Aspiration thrombectomy continues to have a role in contemporary PPCI for STEMI.
- In select cases, Mechanical Thrombectomy may be considered as a bailout in patients with heavy thrombus burden when Manual Aspiration is unsuccessful

References

1. Zack PM, Ischinger T, Aker UT, Dincer B, Kennedy HL. The occurrence of angiographically detected intracoronary thrombus in patients with unstable angina pectoris. American heart journal. 1984;108(6):1408-12.
2. Bresnahan DR, Davis JL, Holmes DR, Jr., Smith HC. Angiographic occurrence and clinical correlates of intraluminal coronary artery thrombus: role of

unstable angina. J Am Coll Cardiol. 1985;6(2):285-9.
3. Zhao XQ, Theroux P, Snapinn SM, Sax FL. Intracoronary thrombus and platelet glycoprotein IIb/IIIa receptor blockade with tirofiban in unstable angina or non-Q-wave myocardial infarction. Angiographic results from the PRISM-PLUS trial (Platelet receptor inhibition for ischemic syndrome management in patients limited by unstable signs and symptoms). PRISM-PLUS Investigators. Circulation. 1999;100(15):1609-15.
4. Sianos G, Papafaklis MI, Serruys PW. Angiographic thrombus burden classification in patients with ST-segment elevation myocardial infarction treated with percutaneous coronary intervention. J Invasive Cardiol. 2010;22(10 Suppl B):6B-14B.
5. The Thrombolysis in Myocardial Infarction (TIMI) trial. Phase I findings. TIMI Study Group. The New England journal of medicine. 1985;312(14):932-6.
6. Van't Hof AW, Liem A, Suryapranata H, Hoorntje JC, de Boer MJ, Zijlstra F. Angiographic assessment of myocardial reperfusion in patients treated with primary angioplasty for acute myocardial infarction: myocardial blush grade. Zwolle Myocardial Infarction Study Group. Circulation. 1998;97(23):2302-6.
7. Gibson CM, de Lemos JA, Murphy SA, Marble SJ, McCabe CH, Cannon CP, et al. Combination therapy with abciximab reduces angiographically evident thrombus in acute myocardial infarction: a TIMI 14 substudy. Circulation. 2001;103(21):2550-4.
8. Yip HK WC, Chang HW, Hsieh YK, Fang CY, Chen SM, Chen MC. Impact of tirofiban on angiographic morphologic features of high-burden thrombus formation during direct percutaneous coronary intervention and short-term outcomes. Chest. 2003;124(3):962-8.
9. Henriques JP ZF, Ottervanger JP, de Boer MJ, van 't Hof AW, Hoorntje , JC SH. Incidence and clinical significance of distal embolization during primary angioplasty for acute myocardial infarction. Eur Heart J. 2002;23(14):1112-7.
10. Stone GW, Peterson MA, Lansky AJ, Dangas G, Mehran R, Leon MB. Impact of normalized myocardial perfusion after successful angioplasty in acute myocardial infarction. J Am Coll Cardiol. 2002;39(4):591-7.
11. Svilaas T, Vlaar PJ, van der Horst IC, Diercks GF, de Smet BJ, van den Heuvel AF, et al. Thrombus aspiration during primary percutaneous coronary intervention. The New England journal of medicine. 2008;358(6):557-67.
12. Vlaar PJ, Svilaas T, van der Horst IC, Diercks GF, Fokkema ML, de Smet BJ, et al. Cardiac death and reinfarction after 1 year in the Thrombus Aspiration during Percutaneous coronary intervention in Acute myocardial infarction Study (TAPAS): a 1-year follow-up study. Lancet. 2008;371(9628):1915-20.
13. Sardella G, Mancone M, Bucciarelli-Ducci C, Agati L, Scardala R, Carbone I, et al. Thrombus aspiration during primary percutaneous coronary intervention improves myocardial reperfusion and reduces infarct size: the EXPIRA (thrombectomy with export catheter in infarct-related artery during primary percutaneous coronary intervention) prospective, randomized trial. J Am Coll Cardiol. 2009;53(4):309-15.
14. De Luca G, Dudek D, Sardella G, Marino P, Chevalier B, Zijlstra F.

Adjunctive manual thrombectomy improves myocardial perfusion and mortality in patients undergoing primary percutaneous coronary intervention for ST-elevation myocardial infarction: a meta-analysis of randomized trials. Eur Heart J. 2008;29(24):3002-10.
15. Burzotta F, De Vita M, Gu YL, Isshiki T, Lefevre T, Kaltoft A, et al. Clinical impact of thrombectomy in acute ST-elevation myocardial infarction: an individual patient-data pooled analysis of 11 trials. Eur Heart J. 2009;30(18):2193-203.
16. Task Force on the management of ST segment Elevation Myocardial Infarction of the ESC, Steg PG, James SK, Atar D, Badano LP, Blomstrom-Lundqvist C, et al. ESC Guidelines for the management of acute myocardial infarction in patients presenting with ST-segment elevation. Eur Heart J. 2012;33(20):2569-619.
17. American College of Emergency P, Society for Cardiovascular Angiography Interventions, O'Gara PT, Kushner FG, Ascheim DD, et al. 2013 ACCF/AHA guideline for the management of ST-elevation myocardial infarction: a report of the American College of Cardiology Foundation/American Heart Association Task Force on Practice Guidelines. J Am Coll Cardiol. 2013;61(4):e78-140.
18. Russo JJ, Dzavik V, Cairns JA, Rao SV, Niemela KO, Natarajan MK, et al. An international survey of clinical practice during primary percutaneous coronary intervention for ST-elevation myocardial infarction with a focus on aspiration thrombectomy. EuroIntervention. 2013;8(10):1143-8.
19. Chiang A, Gada H, Kodali SK, Lee MS, Jeremias A, Pinto DS, et al. Procedural variation in the performance of primary percutaneous coronary intervention for ST-elevation myocardial infarction: a SCAI-based survey study of US interventional cardiologists. Catheter Cardiovasc Interv. 2014;83(5):721-6.
20. Stone GW, Maehara A, Witzenbichler B, Godlewski J, Parise H, Dambrink JH, et al. Intracoronary abciximab and aspiration thrombectomy in patients with large anterior myocardial infarction: the INFUSE-AMI randomized trial. JAMA : the journal of the American Medical Association. 2012;307(17):1817-26.
21. Frobert O, Lagerqvist B, Olivecrona GK, Omerovic E, Gudnason T, Maeng M, et al. Thrombus aspiration during ST-segment elevation myocardial infarction. The New England journal of medicine. 2013;369(17):1587-97.
22. Jolly SS, Cairns JA, Yusuf S, Meeks B, Pogue J, Rokoss MJ, et al. Randomized trial of primary PCI with or without routine manual thrombectomy. The New England journal of medicine. 2015;372(15):1389-98.
23. Levine GN, Bates ER, Blankenship JC, Bailey SR, Bittl JA, Cercek B, et al. 2015 ACC/AHA/SCAI Focused Update on Primary Percutaneous Coronary Intervention for Patients With ST-Elevation Myocardial Infarction: An Update of the 2011 ACCF/AHA/SCAI Guideline for Percutaneous Coronary Intervention and the 2013 ACCF/AHA Guideline for the Management of ST-Elevation Myocardial Infarction. J Am Coll Cardiol. 2016;67(10):1235-50.
24. Authors/Task Force, Windecker S, Kolh P, Alfonso F, Collet JP, Cremer J, et al. 2014 ESC/EACTS Guidelines on myocardial revascularization: The Task Force on Myocardial Revascularization of the European Society of Cardiology (ESC) and the European Association for Cardio-Thoracic Surgery (EACTS)Developed with the special contribution of the European Association

of Percutaneous Cardiovascular Interventions (EAPCI). Eur Heart J. 2014;35(37):2541-619.
25. BostonScientific. http://www.bostonscientific.com/en-US/products/thrombectomy-systems/angiojet-ultra-coronary-thrombectomy-system.html.
26. Ali A, Cox D, Dib N, Brodie B, Berman D, Gupta N, et al. Rheolytic thrombectomy with percutaneous coronary intervention for infarct size reduction in acute myocardial infarction: 30-day results from a multicenter randomized study. J Am Coll Cardiol. 2006;48(2):244-52.
27. Migliorini A, Stabile A, Rodriguez AE, Gandolfo C, Rodriguez Granillo AM, Valenti R, et al. Comparison of AngioJet rheolytic thrombectomy before direct infarct artery stenting with direct stenting alone in patients with acute myocardial infarction. The JETSTENT trial. J Am Coll Cardiol. 2010;56(16):1298-306.
28. Bavry AA, Kumbhani DJ, Bhatt DL. Role of adjunctive thrombectomy and embolic protection devices in acute myocardial infarction: a comprehensive meta-analysis of randomized trials. Eur Heart J. 2008;29(24):2989-3001.
29. Kumbhani DJ, Bavry AA, Desai MY, Bangalore S, Bhatt DL. Role of aspiration and mechanical thrombectomy in patients with acute myocardial infarction undergoing primary angioplasty: an updated meta-analysis of randomized trials. J Am Coll Cardiol. 2013;62(16):1409-18.