ORIGIAL PAPER

Echocardiographic Anatomy of Ventricular Septal Defects in Sudanese Patients.

Niema Mohamed Hamid Aalim*, Abdelmoneim Adam Abbaker Abdellah**, Sulafa KM Ali^

Ventricular septal defect (VSD) is one of the most frequently encountered congenital heart defects (CHD). Anatomical locations of VSD have important implications on management. A retrospective descriptive echocardiographic study for the anatomical patterns of VSD and associated defects and anatomical complications in Sudanese patients was conducted in two pediatric cardiology centres in Khartoum during the period from January 2008 to January 2013. All patients with VSD as the primary diagnosis (including minor associated defects) were included. In the 543 cases studied, the most common type of VSD was the perimembranous (PM) type in (68%) followed by muscular (13%), malaligned (8%), subarterial infundibular (7%) and multiple VSD (5%). The most common associations were patent ductus arteriosus (PDA) in 9.6% and mitral valve cleft (MVC) in 4% of the PM type and right ventricle outflow tract muscle bundles (RVOTMB) seen in 2.5%. The most common anatomical complication was aortic valve prolapse in 6.2%.The anatomical patterns in Sudanese patients are generally comparable to the literature but the frequencies of MVC is higher than reported.

Introduction:

Ventricular septal defect (VSD) is considered one of the most commonly encountered congenital heart defects (CHD)with a prevalence of 0.3-3.3/1000 live birth. (1,2)Echocardiography (echo) is the gold standard for anatomical and functional assessment of VSDs.

*Department of Human Anatomy, Faculty of Medicine, University of Khartoum.** Department of Congenital Cardiac Sugery, Ahmed Gasim Cardiac Centre, KhartoumNorth, Sudan. ^Department of Pediatric Cardiology, Sudan Heart Institute and Faculty of Medicine , University of Khartoum. Correspondence to: Prof.Sulafa KM Ali, E mail: sulafaali2000@gmail.com

echo anatomy of the defect. Few studies have been done in our region to determine VSD anatomy and this study aims to determine the echo anatomical patterns of isolated VSDs in Sudanese patients.

In addition, echo is vital for the follow up of VSDs to identify their course in terms of spontaneous closure, the need to undergo surgical repair, the presence of associated defects as well as the development of complications with high precision and reliability. VSD anatomy has important implications on management as certain positions do not close spontaneously e.g subarterial VSD and others can lead to serious complications as seen in prolapse of aortic valve cusp into a perimembraneous (PM) or subarterial VSD.(3) In addition, the position of the VSD dictates the surgical approach and potential post operative complications, therefore it is mandatory for the cardiac surgeon to know the detailed

Methodology:

This is a retrospective descriptive hospital based study. It was performed in two pediatric cardiology clinics in Khartoum in

the period January 2008 to January 2013. The patients were evaluated by a pediatric cardiologist, complete 2 dimensional echo/Doppler studies were done using Esoate (MyLab30) machine. The echocardiography reports of patients with primary diagnosis of VSD done during this period were retrospectively reveiwed to determine echo anatomy. Standard segmental sequential analysis was adopted. Classification of VSDs was based on Soto et al anatomical description (4).

Patients with a primary diagnosis of VSD including those with certain additional lesions (atrial septal defects (ASD), mild pulmonary stenosis, mitral valve clefts (MVC) and patent dunctus arteriosus) were included. Patients with major associated anomalies (e.g. atrioventricular septal defect, Tetralogy of Fallot, trucus arteriosus or double outlet right ventricle) were excluded.

Ethical Considerations:

Ethical approval was obtained from the Khartoum University Medical Ethics Committee and permission was obtained from the Cardiology Clinic authorities.

Results:

In the study period a total of 5000 patients with CHD were seen in the 2 clinics, VSD constitutes 775 cases (15% of CHD). In 232 patients (29.9% of patients) the medical records were not adequate for detailed analysis of VSD anatomy so these were excluded and the remaining 543 were analyzed. Males represented 264 (48.6%), and females 279 (51.4%).

Neonates were 33 (6.1%), infants 294 (54.1%), 1-5 years 127 (23.4%), 5-15 years 70 (12.9%), and adults (18 – 40 years) were19 (3.5%).

The anatomical types are shown in figure1 and the types of PM VSDs in table1. PM defects were 367 (67.5%), the most common was PM outlet in 45.1%.

Muscular defects were 73 cases (13.4%), of these muscular trabecular defects were 49 (68%), muscular outlet defects were 13 (17%) and muscular inlet 13 cases (15%).

The sizes of the defects varied from <0. 2cm to 2.5 cm with 80% measuring between 0.4mm-1.2cm.

In 136 (25%) of the cases the defect was associated with another minor intracardiac congenital anomaly, PDA in 8.5%, atrial septal defect in 6.6%, MVC in 1.7% of all VSDs and 4% of PM type. Mild pulmonary valve stenosis in 1.1%, the remaining were combinations of the above. Sixty five (12%) of VSDs were restricted, 58 (90%) by a pseudoaneurysm of the tricuspid valve and 7(10%) by the moderator band. Anatomical complications were seen in 11% of patients as

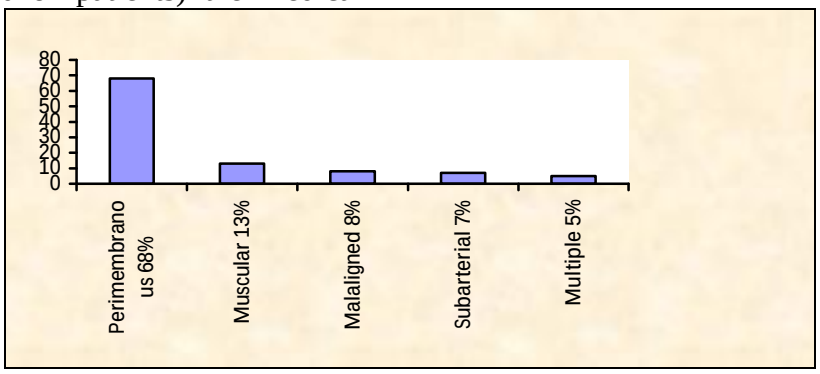

Figure 1: Percentage of anatomical types of VSD

Type of PM VSD	Number	%
PM outlet	245	66.7
PM inlet/ outlet (confluent)	93	25.3
PM inlet	29	8
Total	367	100

Table 1: The types of Perimembranous Ventricular Septal Defects (n=367)

shown in Table 2. The most common complication was aortic valve prolapse seen in 33 patients (Figure 2), all of whom had PM VSDs representing 9.7% of these patients. Subaortic membrane and RVOTMB were additional less frequent complications/associations. (Figures 3)

The anatomical type of the VSD had a significant association with MVC (*p*-value 0.01). There were 16 cases of MVC; 15 were associated with PM defects (5 inlet (17%), 5 inlet/outlet (5.3%) and 5 outlet (2%). (*p* value 00.00). RVOTMB was significantly associated with PM outlet VSDs (p-value 0.019), there were 13 cases complicated with development of RVOTMB (11 PM outlet defects, 2 PM inlet outlet). Associations with the other complications were insignificant.

Complications/Associasions	Frequency	Percent
Aortic valve prolapse	27	5.0
Subaortic Membrane	17	3.1
RVOT muscle bundle	10	1.8
Aortic valve prolapse + sub aortic membrane	3	0.6
Aortic valve prolapse +RVOT muscle bundle	2	0.4
Aortic valve prolapse + RVOTMB + sub aortic	1	0.2

membrane		
Total	**60**	**11.1**

Table 2: Anatomical complications/associations

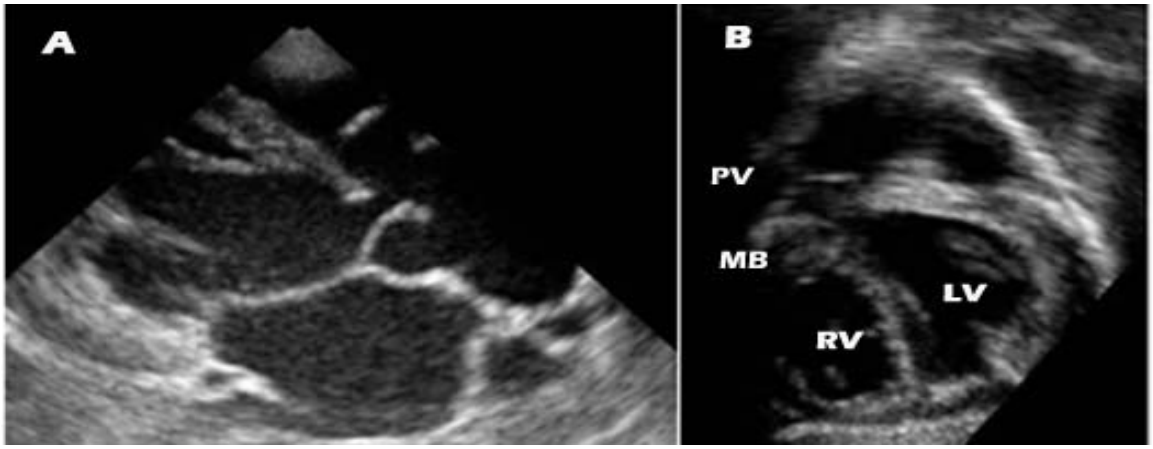

Figure 2. Panel A: parasternal long axis view showeing prolapse of the aortic valve cusp into the VSD. Panel B: Subcostal coronal veiw of the right ventricle outflow tract showing muscles (MB) below the pulmonary valve (PV). RV = right ventricle; LV = left ventricle

Discussion:

In this series, PM VSDs were the commonest type which is in agreement with the reveiwed literature. The percentage of the different types of VSDs was similar to that reported by Soto et al, Al Abbaqe and Kazmi (4,5,6). Few studies were done in Sub Saharan Africa, in general the VSD common anatomic sites were comparable to a study done in Nigeria (7)

Identification of inlet extension of VSD (which in our study was one third of PM defects) is of important clinical significance as the position of the atrioventricular node at the base of the VSD should be carefully observed by the cardiac surgeon in order to avoid post operative heart block (8).

Diagnosis of associated defects is crucial since many of them may lead to complications. In this study mitral valve cleft was seen in 7% of PM VSD, mainly with the inlet type. Echocardiographers need to look carefully at this defect as mitral valve function may be normal at the time of VSD closure but may deteriorate later needing repeated open heart surgery. Mitral valve clefts associated with inlet VSD need to be differentiated from atrioventricular septal defects, both conditions are associated with Down's syndrome. (9) This can be readily achieved by scanning of subcostal views (enface view) to look for a common atrioventricular junction (in atrioventricular septal defect). Moreover, measurement of the left ventricle inlet/outlet ratio and the relative size of the mitral (or left atrioventriclur valve) posterior (mural) leaflet has been shown to have a value in differentiating these two conditions (10).

The most common complication in the literature is aortic valve prolapse ranging from 4-10% (6,11) similar to our finding of 6% of VSDs and 9.7% of the cases of PM outlet and confluent VSDs.

This complication is of clinical importance as the delay in echo diagnosis can lead to serious complications of aortic regurgitation, e.g secondary dilated cardiomyopathy, and the need for aortic valve replacement if not diagnosed early. (12).

The incidence of RVOTMB, associated with VSD is not accurately known. Due to their progressive nature, the frequency of detections increases with increasing age as well as the method of detection (echo versus anatomical examination). In a natural history study of 790 patients followed up to 25 years, infundibular stenosis began to evolve in 7% of patients. (13).

In our series, RVOTMB was seen in 2.4% of patients. It is therefore important to look carefully for these mucles and and follow up RVOT gradients as they increase with time. Severe gradients will be indications for surgery.

Conclusion:

We described the echocardiographic anatomy of VSD and found that the patterns and complications were generally comparable to literature but the frequencies of MVC is higher than reported and it is significantly associated with PM inlet VSD.

Limitations:

Retrospective nature of this study , missing data and the fact that the images were not validated by a second observer limit the accuracy of this study.

Recommendations:

Echocardiographers need to examine carefully for anatomical position, associations and complications of VSD in order to plan medical or surgical management.

References:

1.Moore KL, Persaud T.V.N, Torchia MG. The Developing Human: Clinically Oriented Embryology. 9th Ed. Canada: Saunders; 2013, 289-342.

2. Mitchell SC, Korones SB, Berendes HW. Congential heart disease in 56,109 birth, incidence and natural history. Circulation 1971;43:323-32

3.Sutherland GR, Godman MJ, Keeton BR, Shore DF, Bain HH, Hunter S, Natural history of perimembranous ventricular septal defects: a prospective echocardiographic haemodynamic correlative study. Br Heart J, 1984;51:682.

4.Soto B, Becker AE, Moulaert AJ, Lie JT, Anderson RH, Classification of ventricular septal defects, British heart journal,1980;43:332-43.

5.Abbag F. The natural history of ventricular septal defects in the south-western region of Saudi Arabia. Annals of Tropical Pediatrics 2006;26:215-8

6.Kazmi U, Sadig M, Hyder SN,Pattern of ventricular septal defects and associated complications,J Coll Physicians Surg Pak,2009;19:342-5.

7.Wilson E Sadoh. Natural history of ventricular septal defects in Nigerian children. South African J of Childhealth,2010;4:16-19.

8.Milo S, Ho SY, Wilkinson JL, Anderson RH. Surgical anatomy and atrioventricular conduction tissues of hearts with isolated ventricluar septal defects. J Thorac Cardiovasc Surg.1980;79:244-55.

9.Ali SK. Cardiac abnormalities of Sudanese children with Down's syndrome and their short term outcome.Cardiovasc J Afr. 2009;20:112-5.

10.K.M.A.Sulafa, O.R.Tamimi, Hani K.Najm, M.J.Godman Echocardiographic differentiation
of atrioventricular septal defects from inlet ventricular septal defects and mitral valve clefts.AmJ
Cardiol. 2005 Mar 1;5:607-10.

11.Karpawich PP, Duff DF, Mullins CE, Cooley DA, Mc Namara DG.Ventricular septal defect with associated aortic valve insufficiency, progression of insufficiency and operative results in young children.J Thorac Cardiovasc Surg.1981;82:182-9.
12.Hisatomi K, Kosuga K, Isomura T, Akagawa H, Ohishi K, Koga M. Ventricular septal defect associated with aortic regurgitation. Ann Thorac Surg. 1987;43:363-7
13.Corone P, Dovon F, Gaudeau S et al. Natural history of ventricular septal defect. A study involving 790 cases. *Circulation* 1977;55:908–15.