CARDIOLOGY IMAGES

Aberrant Crossed Left Anterior Descending and left Circumflex Arteries from Right Coronary Artery with Obstructive Coronary Artery Disease

Yousri Daoud, Mohamed Balgaith, Z. Elsherif, Amira Ahmed, Ahmed Alsaileek
King Abdulaziz Medical City, Ministry of National Guard Health Affair, Riyadh, Saudi Arabia

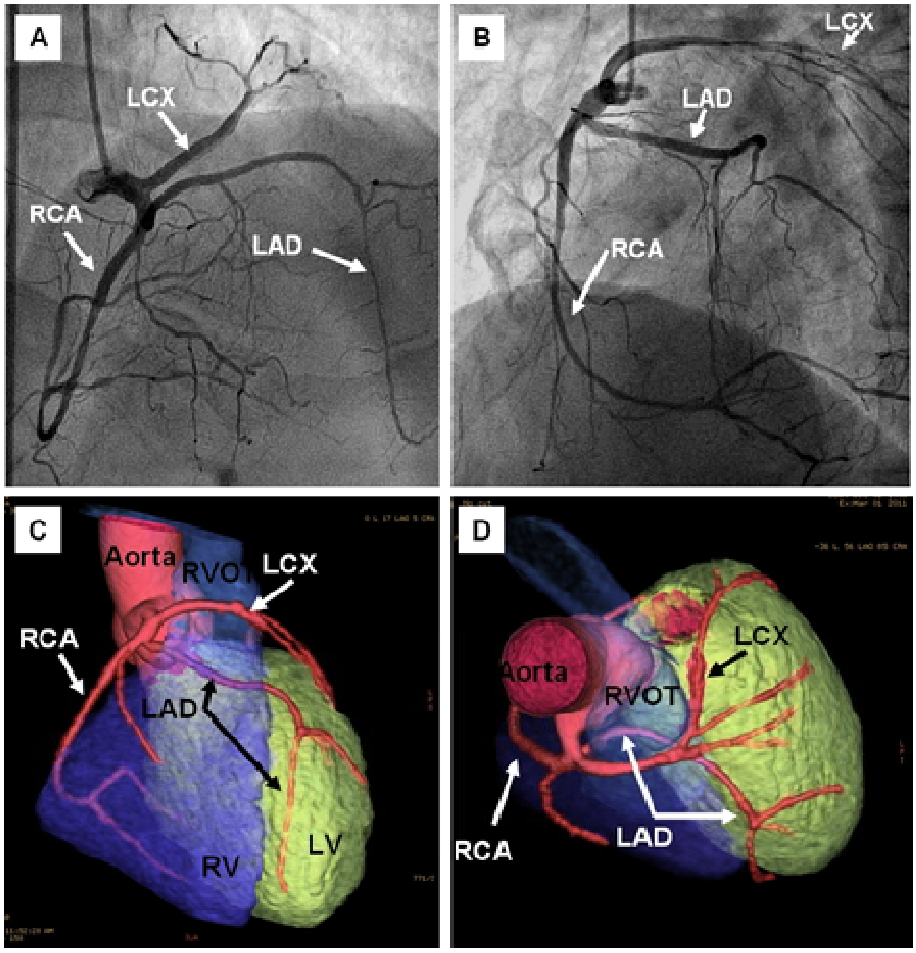

Figure Legend: Single coronary artery arising from the right sinus of Valsalva, in right anterior oblique projection giving right coronary artery, left anterior descending artery and left circumflex coronary artery (A & B), Multislice spiral computed tomography showed the single coronary artery arising from the right sinus of Valsalva. The left anterior descending artery turns posteriorly between the aorta and pulmonary artery and the left circumflex coronary artery runs anterior around the main pulmonary artery (C & D).

Anomalous origin of coronary arteries is rare in patients who undergone coronary artery angiography. Finding all the coronary arteries originating from a single ostium is extremely rare (1, 2). In addition, most patients with anomalous coronary arteries have no obstructive coronary artery disease (CAD). We present a case of anomalous origin of left anterior descending artery and circumflex coronary artery with very unusual course and severe coronary artery disease.

A 57-year-old male presented with 2-3 month history of stable angina on mild exertion. He is ex-smoker and known to have hypertension and dyslipidemia, Cardiac catheterization revealed anomalous origin of left anterior descending artery (LAD) and left circumflex coronary artery (LCX) from the right coronary artery (RCA). In addition there was severe and diffuse CAD of the LAD and the LCX (Figure A & B). Coronary computed tomography angiography demonstrated detailed anatomical course of the coronary arteries (Figure C & D). The courses of the coronary arteries were very unusual. LCX crossed anterior to the main pulmonary artery and the LAD crossed between the aorta and the main pulmonary artery. This gave a picture of crossed coronary arteries around the pulmonary artery. Because of obstructive CAD the patient underwent coronary artery bypass grafting where the findings were confirmed. The patient, then, had uneventful post-operative course.

References

1. Desmet W, Vanhaecke J, Vrolix M, Van de Werf F, Piessens J, Willems J, et al. Isolated single coronary artery: a review of 50,000 consecutive coronary angiographies. Eur Heart J 1992;13(12):1637-40.
2. Yamanaka O, Hobbs RE. Coronary artery anomalies in 126,595 patients undergoing coronary arteriography. Cathet Cardiovasc Diagn 1990;21(1):28-40.