CASE REPORTS

Cavernous Transformation of Portal vein associated with Left Atrial Myxoma

Faisal Ahmed EL-Mustafa Suliman MRCP, FRCP, Abduelbagi Dafaallah A Altayb MBBS*

Primary cardiac tumors are rare and they are mostly benign [1]. Myxoma is the commonest and mainly seen at left atrium. When symptoms develop; they are mostly related to obstruction of mitral valve, followed by embolic and systemic manifestation [2]. Surgical removal is the definitive treatment. Left atrial myxoma, have been rarely reported in association with venous thrombosis, or it is complications [8,10]. Cavernous Transformation of Portal vein (CTPV) is the end result of acute portal vein thrombosis evolution. In adult mainly it is due to hepatocellular carcinoma, cirrhosis, pancreatitis and liver transplant [6]. CTPV lead to portal vein hypertension and port-systemic shunt mainly through left gastric vein leading to gastric varices, But may be asymptomatic[7].In this case report, we describe a patient with large Left atrial Myxoma who developed portal vein thrombosis.

Key word: Cavernous Transformation of portal vein – left atrial myxoma – Portal vein thrombosis

Case Report

A 38-year-old house wife was referred for further investigations of syncopal attacks.

Four year before, she developed severe shortness of breath during her last pregnancy, but ended with normal vaginal delivery. She started to use Oral contraceptive pills (OCPs) after that. Three month prior to referral, she had a TIA (transient right side weakness) and was advised to stop OCPs. One month later she was admitted to the hospital with congestive heart failure, Jaundice and recurrent syncopal attacks. She has history of low grade fever and weight loss for 3 month.

* Ahmed Gasim Cardiac Surgery and Renal Transplant Center. Adult Cardiology Department. Khartoum North. Sudan.

Manuscript received on 11/7/2016, accepted on 10/8/2016. Corresponding author: Faisal AM Suliman: faisal.suliman@uofk.edu

On examination, In sinus rhythm PR 81/bpm and normal BP 100/70. Cardiovascular examination showed loud S1 with mid-diastolic rumbling murmur and pulmonary hypertension evidenced by palpable loud P2, and left parasternal heave. Abdominal examination Revealed 9 cm enlarged spleen below the left costal margin. Liver not enlarged. Other systems were normal.

Laboratory investigation revealed Hb 10.4 g/dl, MCV 74 fL, platelets 64,000/mcl, Retic count 1.5% and ESR 30. ECG showed broad P wave in limb lead and CXR showed mild pulmonary congestion. Renal and liver function test were normal. Blood culture was negative,

Echocardiography revealed left atrial mass, with lobulated borders, (6×8)cm size, Mobile with stalk attached to the atrial septum and prolapsing into left ventricle in diastole [Figure 1]. There is mild mitral regurgitation

and severe tricuspid regurgitation PSAP of 81 mmHg. Abdominal US showed splenomegaly of 19.2 cm and mild ascites with portal vein cavernous transformation. Abdominal CT with contrast confirms the diagnosis of PV cavernous transformation due to portal and splenic vein thrombosis [Figure 2].

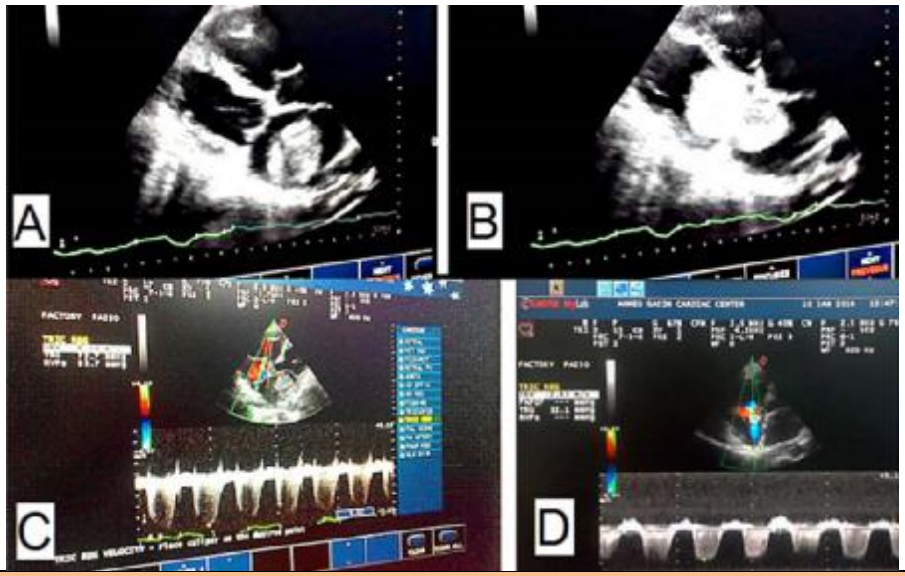

Figure 1. Echocardiographic features of left atrial myxoma. Two-dimensional echocardiography images. Panel A, Parasternal long axis view showing large mass in the left atrium. B, the mass prolapsing through the mitral valve in diastole. C, Continuous-wave Doppler of tricuspid regurgitation due to severe Pulmonary HTN. Panel D, Postoperative Doppler showing improvement of Pulmonary HTN.



Figure 2. Cavernous transformation of portal vein (CTPV) Abdominal CT with Contrast. Panel A: Showing CTPV (red arrow) Panel B shows Gastric varices(yellow arrow). In both panels note the absence of portal and splenic veins.

Stool, Urine, and Serology for Bilharzia were negative. Protein C, Protein S, and antiphospholipid antibodies normal. ANA profile normal. Negative viral screen (HBV, HCV, HIV). Upper GIT endoscopy revealed extensive gastric varices.

Patient underwent urgent surgical resection of her atrial mass. Histopathological examination confirmed the diagnosis of myxoma [Figure 3]. Two month post-operative she was asymptomatic and Echo was normal.

Comments

Venous thrombosis with its complications has been reported with right atrial myxoma. Portal venous thrombosis and budd-Chiari syndrome, were reported by Onan B [4] and his colleagues and Cujec B and his colleagues [5] respectively. They implicated mechanical venous obstructions to right atrium as risk factor.

There is increased evidence that cardiac myxoma secrete a variety of growth factors and cytokines which promote thrombus formation [8,9]. Left atrial myxoma has

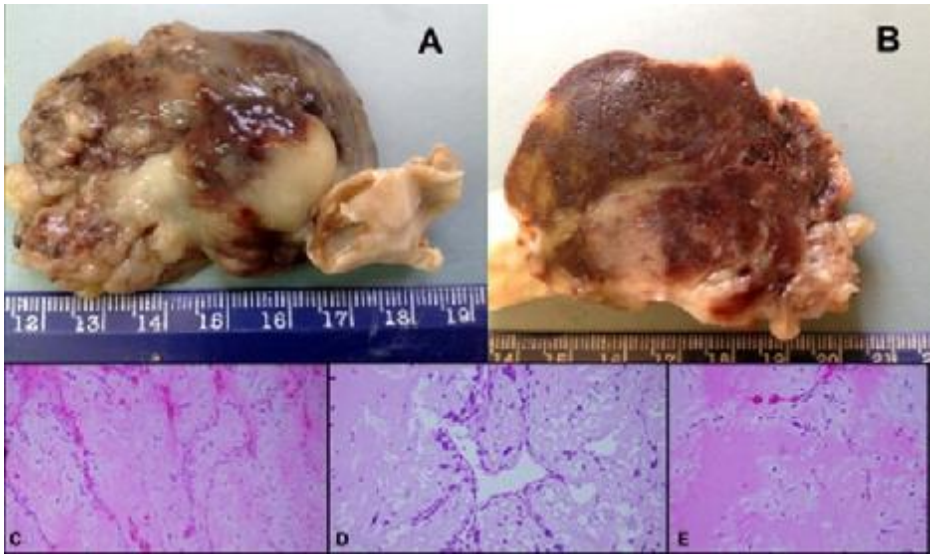

Figure 3. Panel A: Irregular lobulated mass with glistening outer surface. Panel B: Extensive hemorrhage in cut section with areas of myxoid and cystic degeneration. Panel C: Microscopy of atrial myxoma shows delicate vascular channels forming network in myxoid stroma with haemorrhagic foci. Panel D: Characteristic stellate cells around blood vessels in myxoid oedematous stroma. Panel E: Microscopy shows stellate slender cells & foamy macrophages in myxoid stroma

been reported with venous thrombosis and systemic embolism. The latter is most likely due to detachment of small fragments from the tumor or small thrombi on the tumour surface. Redford DT et al, reported case of pulmonary embolism with left atrial myxoma, and they attributed this PE to hemolysis, heme oxygenase-1 up-regulation, systemic hypercoagulability/ hypofibrinolysis, and regional venous stasis[10]. Reto Nagele et al, also reported a case of pulmonary embolism with left atrial myxoma and large type two atrial septal defect. They think embolism resulted from left atrial myxoma prolapsing to right atrium through the ASD[7]. Sonal et al, reported case of left atrial myxoma with concurrent saddle pulmonary embolism and Duke's B Colorectal Adenocarcinoma, they attributed this embolism to metastasized colorectal adenocarcinoma [3].Our patient may have had increased coagulopathy, related to several factors. The presence of the tumor, and venous congestion with HF. The use of OCPs can't be ruled out as a contributory factor[11].

We recommend echocardiography to rule out cardiac myxoma in patients with portal or hepatic venous thrombosis with no obvious predisposing factors.

Acknowledgement

We are grateful to Dr. Abdelsatir AA, for production and commenting on the Histopathological pictures, and Dr. Bakheet YM, for help in selecting of CT Photos

References

1. Lenihan DJ, Yusuf SW. Tumors Affecting the Cardiovascular System. In: Braunwald's Heart Disease: A Textbook Cardiovascular Medicine. Tenth edition. Philadelphia, PA: Elsevier; 2015. p. 1863–9.

2.Pinede L, Duhaut P, Loire R. Clinical Presentation of Left Atrial Cardiac Myxoma. Medicine (Baltimore). 2001 May;80(3):159–72.

3. Sonal M, Parviz Y, Al-Mohammad A. Left Atrial Myxoma With Concurrent Saddle Pulmonary

Embolism and Duke's B Colorectal Adenocarcinoma. J Med Cases. 2013;4(6):398–401.
4. Onan B, ZBayramoğlu Z, Onan İS, Akpınar B. Right atrial myxoma associated with portal and splenic vein thrombosis in a patient with Budd-Chiari syndrome. Turk Kardiyol Dern Ars. 2011 Jun 1;39(4):320–4.
5. Cujec B, Ulmer B, Mckaigney JP, Bharadwaj B. Right Atrial Myxoma Presenting as Budd-Chiari Syndrome. The Annals of Thoracic Surgery. 1987;44(6):658–9.
6. Denninger M-H, Chaït Y, Casadevall N, Hillaire S, Guillin M-C, Bezeaud A, et al. Cause of portal or hepatic venous thrombosis in adults: The role of multiple concurrent factors. Hepatology. 2000;31(3):587–91.
7. Sanyal AJ. Acute portal vein thrombosis in adults: Clinical manifestations, diagnosis, and management [Internet]. Chopra S, Travis AC, editors. Acute portal vein thrombosis in adults: Clinical manifestations, diagnosis, and management. UpToDate; 2014 [cited 2016Jan1]. Available from: http://www.uptodate.com/contents/acute-portal-vein-thrombosis-in-adults-clinical-manifestations-diagnosis-and-management
8. Nagele R, Bonetti PO, Mayer KA. A patient with pulmonary embolism and a mass in the left atrium. Heart. 2012;98(16):1260–.
9. Acebo E, Val-Bernal JF, Gómez-Román JJ, Revuelta JM. Clinicopathologic Study and DNA Analysis of 37 Cardiac Myxomas. Chest. 2003;123(5):1379–85.
10. Redford DT, Thompson JL, Mcculloch JC, Nielsen VG. Left atrial myxoma presenting as pulmonary embolism: potential role of heme oxygenase-1. Blood Coagulation & Fibrinolysis. 2014 Sep;25(6):621–4.
11- Chu G, Farrell GC. Portal vein thrombosis associated with prolonged ingestion of oral contraceptive steroids. J Gastroenterol Hepatol Journal of Gastroenterology and Hepatology. 1993;8(4):390–3.