REVIEW ARTICLE

Evaluation of cardiac sources of embolism

Dr. Saad A. Subahi MBBS FRCP
Associate professor, Consultant cardiologist, The National University, Khartoum, Sudan.
Email; sasubahi@yahoo.com

Abstract
Cerebrovascular disease is a leading cause of mortality and morbidity .20% of cerebral infarcts are due to cerebral embolism of cardiac origin. Conditions associated with cardiogenic emboli are either rhythm abnormalities such as atrial fibrillation (AF) responsible for 50% , or structural abnormalities .Whereas left ventricle thrombus ,left atrium thrombus ,vegetation , tumor and protruding atherosclerotic plaque are considered as direct sources of embolization , others such as valvular disease , wall motion abnormality , atrial septal defect (ASD) , patent foramen ovale (PFO) , atrial septal aneurysm (ASA) and spontaneous echocardiographic contrast (SEC) are considered as indirect cardiac sources of embolization . In this article evaluation of cardiac sources of embolism and the role of echocardiography are discussed. Though both transthoracic echocardiography (TTE) and transesophageal echocardiography (TEE) play an important role, TEE appears to be more sensitive in identifying potential abnormalities in patients with suspected cardiac sources of emboli.

Key words: Subahi, cardiac, embolization.

Introduction

Cerebrovascular disease is a leading cause of death and chronic disability affecting people of all age groups [1]. Approximately 20% of all cerebral infarcts are due to cerebral embolism of cardiac origin [2]. In young patients embolism may be responsible for an even greater proportion of cerebral infarctions.

Review

Conditions associated with cardiogenic emboli are either rhythm abnormalities such as AF and sick sinus syndrome or structural abnormalities. Among the structural abnormalities left atrial thrombus ,left ventricular thrombus, tumour ,vegetation and protruding atherosclerotic plaque are considered as direct or definite cardiac sources of emboli ,whereas others such as valvular disease ,wall motion abnormalities , ASD, PFO , ASA and SEC are considered as potential or indirect cardiac sources of emboli .Alternatively others have classified the first group as high risk sources and the second group as low risk or undetermined risk sources .

Evaluating patients with suspected cardiac sources of embolism begins with clinical cardiac assessment and basic investigations including an electrocardiogram .This is followed in the majority of patients with transthoracic echocardiogram .The role of

TTE in evaluating patients with cerebral or ischaemic events has been assessed in many studies.Most of the studies showed the yield to be low .However the yield was higher in the subgroup of patients with clinically identifiable cardiac disease [3,4,5] .If TTE showed a structurally normal heart, bubble contrast TTE study should be performed to exclude intracardiac shunting. In contrast to TTE, TEE is more valuable in the evaluation of patients with suspected systemic emboli of cardiac origin.TEE identified potential abnormalities in up to 50% of patients with suspected cardiac sources of emboli as compared to 15 % by TTE [6] . Advantages of TEE include improved overall image quality and the ability to image regions not seen well by TTE i.e left atrial appendage [7] , atrial septum and the thoracic aorta . TEE also has increased sensitivity in detecting potential sources of emboli PFO [8] and SEC .

1) **Direct (High risk) cardiac sources of emboli :-**
   a) **Left ventricle thrombus :-**
   Left ventricle thrombus is associated with acute myocardial infarction in the majority of cases .The apex is the usual location in patients with extensive antero-apical infarcts particularly with aneurysm formation. However thrombus may form in cases with small infarcts involving the distal segments of the left ventricle apex. Large ventricle thrombi can also form in patients with severe left ventricle dysfunction due to any cause (Figure 1 Panel A).

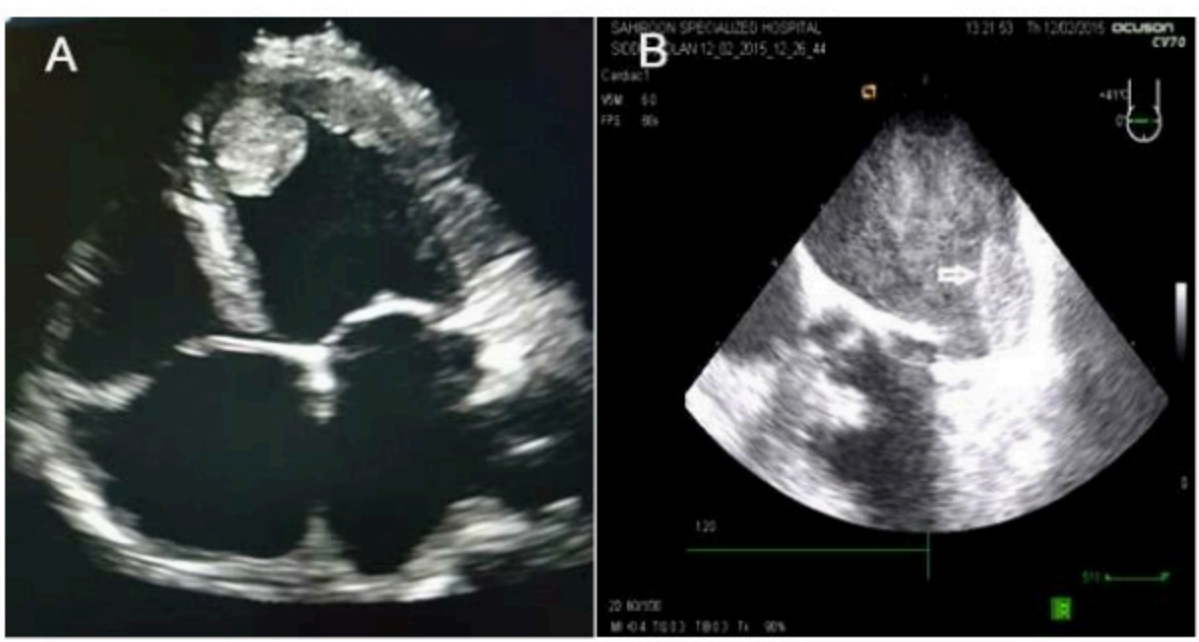

Figure 1. Panel A: TTE (apical 4-c view). Thrombus seen in the left ventricle apex in a patient with peripartum cardiomyopathy. Panel B: TEE showing a thrombus (arrow) and spontaneous echo-contrast in the left atrium of a patient with obstructed mitral valve mechanical prosthesis .

b) Left atrium thrombus:-

Thrombi in the left atrium are usually associated with AF and are commonly located in the left atrium appendage.Left atrial thrombi can form in patients with mitral stenosis particularly in association with AF, in patients with mechanical valve prostheses particularly malfunctioning mechanical valves , in patients with ASAs and rarely in patients with restrictive cardiomyopathy with high left atrial pressure. (Figure 1: Panel B)

c) Infective endocarditis :-

In patients with infective endocarditis the risk of embolism is 10-30% .Echocardiographic features of increased risk are the size(more than 10mm) and mobility of vegetations. In presence of prosthetic valve endocarditis TEE has high sensitivity (86-94%) and specificity (88-100%) for the detection of vegetations as compared to TTE. Figure (2)

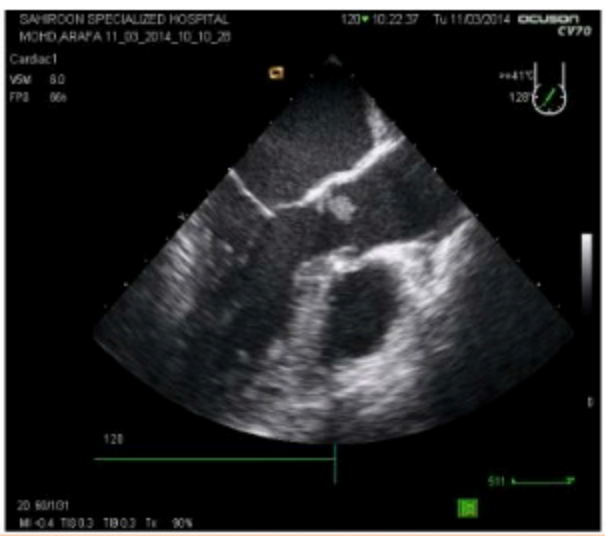

Figure 2: TEE demonstrating a large vegetation attached tothe non-coronary cusp of the aortic valve .

d) Cardiac tumor:-

Cardiac tumors such as myxomas and fibroelastomas are recognized sources of embolic events either by direct embolization or embolization from a thrombus attached to the tumor. In patients with cardiac tumors detected by TTE, TEE provides better visualization and more diagnostic information. Fig (3)

e) Protruding atherosclerotic plaque

Patients with mobile pedunculated aortic atherosclerotic plaques are at increased risk of embolic events. The risk is even higher in patients undergoing invasive procedures involving the abnormal aortic region. Figure (4)

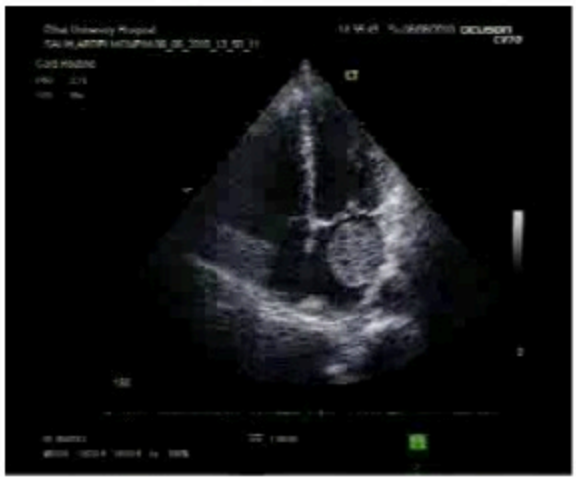

Figure 3: TTE (apical 4-c view) of a patient with a mass (myxoma) within the left atrium cavity.

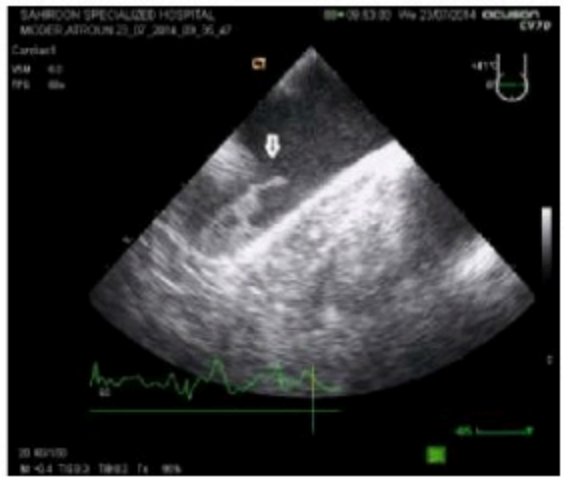

Figure 4: TEE of atherosclerotic plaque with a pedunculated thrombus in the aortic arch. (Arrow)

2) **Indirect (low risk) cardiac sources of embolism:-**

a) **Paradoxical embolism** through either a PFO or ASD has been recognized as a cause of cardiogenic embolization for many years [9, 10]. However several studies have suggested that paradoxical embolization through a PFO may be a much more common cause of paradoxical embolization than previously thought. [11, 12]. PFO has been found on autopsy in up to 35% of the healthy population. However a higher prevalence (40-73%) of PFO was noted in young stroke patients. [11,13] suggesting a clear association between the occurrence of stroke and the presence of a PFO. Figure (5)

b) **Spontaneous echocardiographic contrast (SEC)**

SEC is described as swirling smoke like ultrasound reflection or as dynamic echoes curling in a circular pattern within the cardiac chambers most commonly seen in low flow state . It is commonly seen in patients with chronic AF with or without mitral valve disease in the presence of a large left atrium. SEC can also be seen in the left ventricle in patients with severe global dysfunction. Its association with left atrial thrombus in many patients suggests that patients with SEC are at increased thrombotic risk. [14]

c) **Atrial septal aneurysm (ASA)**

Criteria proposed by Hanley et al [15] for the diagnosis of ASA by TTE include either an aneurysm involving at least 1.5 cm of the atrial septum and bulging 1.5 cm into either atrial chamber from the plane of the atrial septum or an aneurysm with a total of 1.5 cm excursion during the cardiorespiratory cycle . ASA has

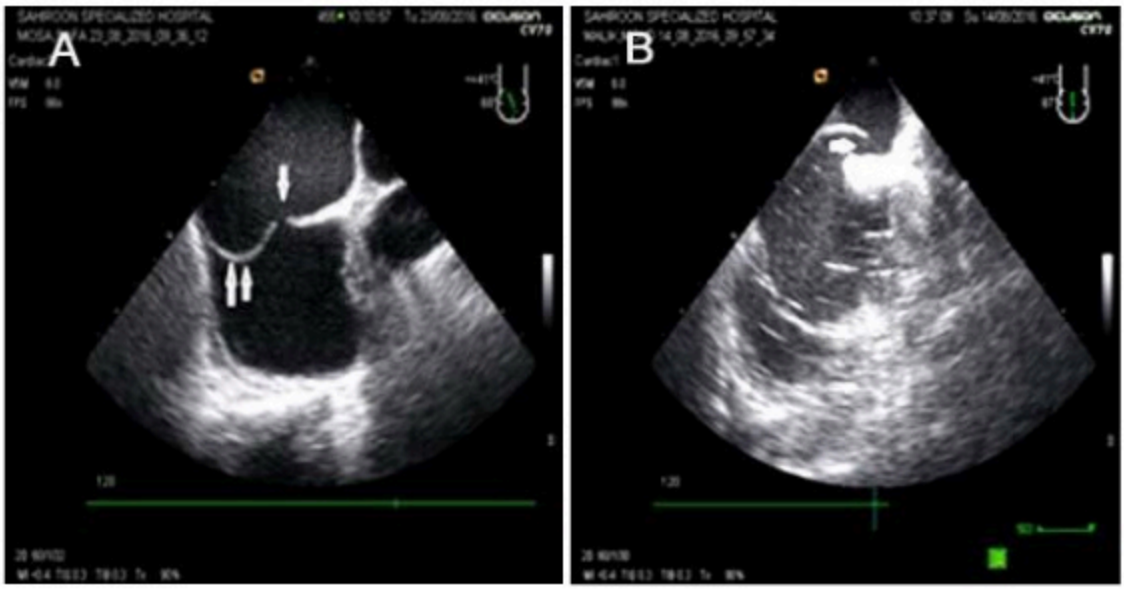

Figure 5. Panel A: TEE showing atrial septal aneurysm (double arrow) with a small ASD (arrow).Panel B: TEE showing a PFO (arrow) in a patient who presented with pulmonary embolism and paradoxicalembolism causing left arm ischaemia .

been reported in a small percentage of patients undergoing TTE for any indication . TEE however identified ASA in approximately 4% of all patients. In patients with unexplained cerebral ischaemia TEE identified ASA in up to 15% of this subgroup. This suggests a clear association between ASA and cardiogenic emboli. However the mechanism by which ASA causes cardiogenic emboli is not clear. Possible explanations include:

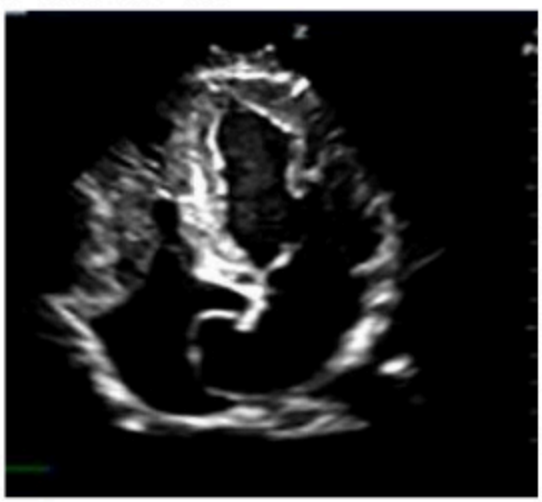

Figure 6: TTE (apical 4-c view) showing a large atrial septal aneurysm.

1) Association with thrombus formation due to blood stasis.
2) Association of ASA with other potential cardiogenic sources of emboli such as PFO, ASD and mitral valve prolapse.
3) Association with AF and other atrial arrhythmias. Figure (6)

Conclusion

For the evaluation of patients with unexplained cerebral ischaemia or suspected cardiac sources of emboli, both TTE and TEE play an important role. However if the clinical examination and basic investigations including an electrocardiogram and a chest x-ray are normal, the yield from TTE is low. The yield is higher (15%) in patients with identifiable cardiac disease e.g. AF, valvular disease, ischemic heart disease etc. TEE however is much sensitive than TTE in that it identified potential abnormalities in up to 50% of patients with suspected cardiac sources of emboli.

Acknowledgement:
I thank Mrs. Rodab Satti for the secretarial work and the echocardiography technologists at Ribat University Hospital for the technical assistance with echocardiography studies.

References

1. Centers for Disease Control: Progress in chronic disease prevention : Chronic disease reports: Mortality trends – United States , 1979 -1986 . MMWR 1989; 38: 189 -201.
2. Asinger RW, Dyken ML, Fisher M, et al. Cardiogenic brain embolism:thesecond report of the Cerebral Embolism Task Force. Arch Neurol 1989; 46:727-43.
3. Lovett IL, Sandok BA, Giuliani ER, Nasser FN.Two-dimensional echocardiography in patients with focal cerebral ischemia. Ann Intern Med 1981; 95: 1-4.
4. Biller J, Johnson MR, Adams HP, et al. Echocardiographic evaluation of young adults with non-hemorrhagic cerebral infarction. Stroke 1986;17:608-12.
5. Greenland P, Knopman OS, Mikell FL, et al. Echocardiography in diagnostic assessment of stroke. Ann Intern Med 1981;95:51-3.
6. Pearson AC, Lobovitz AJ, Tatineni S, et al. Superiority of transesophageal echocardiography in detecting cardiac source of embolism in patients with cerebral ischemia of uncertain etiology. J Am Coll Cardiol 1991;17:66-72.
7. Aschenberg W, Schlitter M , Kremer P , et al . Transesophageal two-dimensional echocardiography for the detection of Ieft atrial appendage thrombus. J Am Coll Cardiol 1986;7:163-166.
8. Mugge A, Daniel WG, Klopper JW, et al : Visualization of patent foramen ovale by transesophageal color-coded Doppler echocardiography. Am J Cardiol 1988;62:837-838.
9. Belkin RN, Kisslo J. Atrial septal aneurysm: Recognition and clinical relevance. Am Heart J 1990; 120:948 -957.
10. Sweeney LJ, Rosenquist GC: The normal anatomy of the atrial septum in the human heart. Am Heart J 1979; 98:194-199.
11. Webster AWI, Smith HJ, Sharpe DN, et al: Patent foramen ovale in young stroke patients. Lancet 1988;2:11- 12.
12. Strunk BL ,Cheitlin MD , Stulbarg MS , et al : Right –to-left interatrial shunting through a patent foramen ovale despite normal intracardiac pressures. Am J Cardiol 1987;60:413-415.
13. Lechat P, Mass LJ, Laschault G, et al : Prevalence of patent foramen ovale in patients with stroke .N Engl J Med 1988 ; 318:1148 – 1152
14. Daniel WG, Nellessen U, Schroder E, et al : Left atrial spontaneous echo contrast in mitral valve disease : An indicator for an increased thromboembolic risk . J Am Coll Cardiol1988 ; 11:1204-1211.
15. Hanley PC, Tajik AJ, Hynes JK , et al : Diagnosis and classification of atrial septal aneurysm by two-dimensional echocardiography : Report of 80 consecutive cases . J Am Coll Cardiol 1985; 6:1370 -1382.