REVIEW ARTICLE

Diagnosis of Constrictive Pericarditis in Multi-Modality Imaging Era

Abdelrahman Jamiel[1,2], MD, FRCP, SFCard, Dalia Ahmed[1,2], MD; Amjad M. Ahmed[1], MBBS MSc; Mouaz H. Al-Mallah[1,2] MD MSc. [1] King Abdul-Aziz Cardiac Center, King Abdul-Aziz Medical City, Ministry of National Guard - Health Affairs, Riyadh, Saudi Arabia. [2] King Saud Bin Abdul-Aziz University for health sciences, Riyadh, Saudi Arabia.

Introduction

Pericardial constriction is a relatively uncommon entity in contemporary practice. The clinical signs and symptoms of pericardial constriction are often vague and may have been present for several years to decades before the diagnosis is finally established. The diagnosis of constriction remains challenging, however, with new insights and advances in noninvasive imaging, a definitive diagnosis of pericardial constriction is becoming easier to establish (1-4). No single diagnostic approach can be used to diagnose all cases of constrictive pericarditis. Multimodality imaging is an integral part of modern management for most, if not all, cardiovascular conditions, including pericardial diseases. Our aim is to review the role of multi-modality imaging in diagnosis of constrictive pericarditis (CP). The discussion of etiology, clinical presentation and management is beyond the scope of this article.

Chest radiograph

The presence of pericardial calcification on chest X-ray in patients with symptoms of right sided heart failure strongly suggests pericardial constriction (Figure 1) (5).

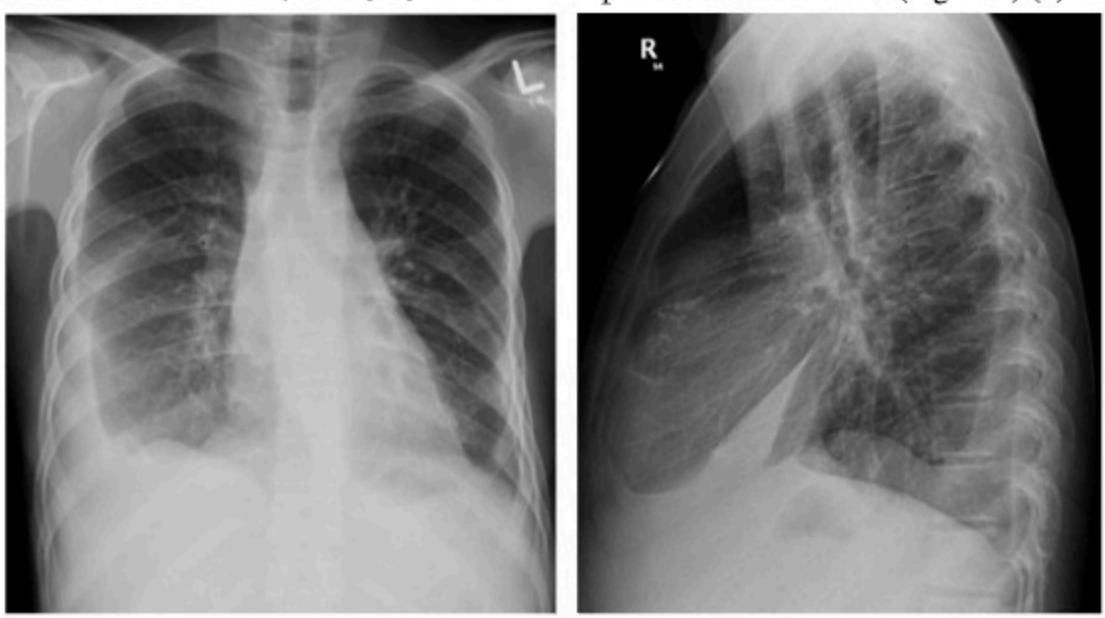

Figure 1: Anteroposterior and lateral chest radiograph from a patient with constrictive pericarditis (shows pericardial calcification and right sided pleural effusion).

The clinical value of calcification of the pericardium in CP was evaluated in a retrospective review of 135 patients with CP which had been confirmed surgically or by autopsy, and only 27% had pericardial calcification (6) Pericardial calcification is associated with a longer duration of the constrictive process but not with a specific

etiology. Therefore, absence of calcification does not exclude CP. Pericardial calcification can occur in the absence of constriction, but is usually less dense and has a patchy distribution. Compared to those without calcification, patients with calcification had a greater likelihood of having idiopathic pericardial disease (67% vs. 21%), a longer duration of symptoms, a greater likelihood of having a pericardial knock, larger atria, and atrial arrhythmias and a higher perioperative mortality, but the same long-term survival (1).

Echocardiography

Echocardiography remains as an initial imaging test in most scenarios because of its ease of use, wide and bedside availability, cost-effectiveness, and comprehensive assessment of both anatomy and physiology. The following echo findings may be present in patients with CP (5,7-13) : (i) increased pericardial thickness, when measured by trans-esophageal echocardiography (TEE) correlates strongly with that obtained by CT, however, CP can occur without increased pericardial thickness; (ii) abnormal ventricular septal motion (septal bounce) (Figure 2)

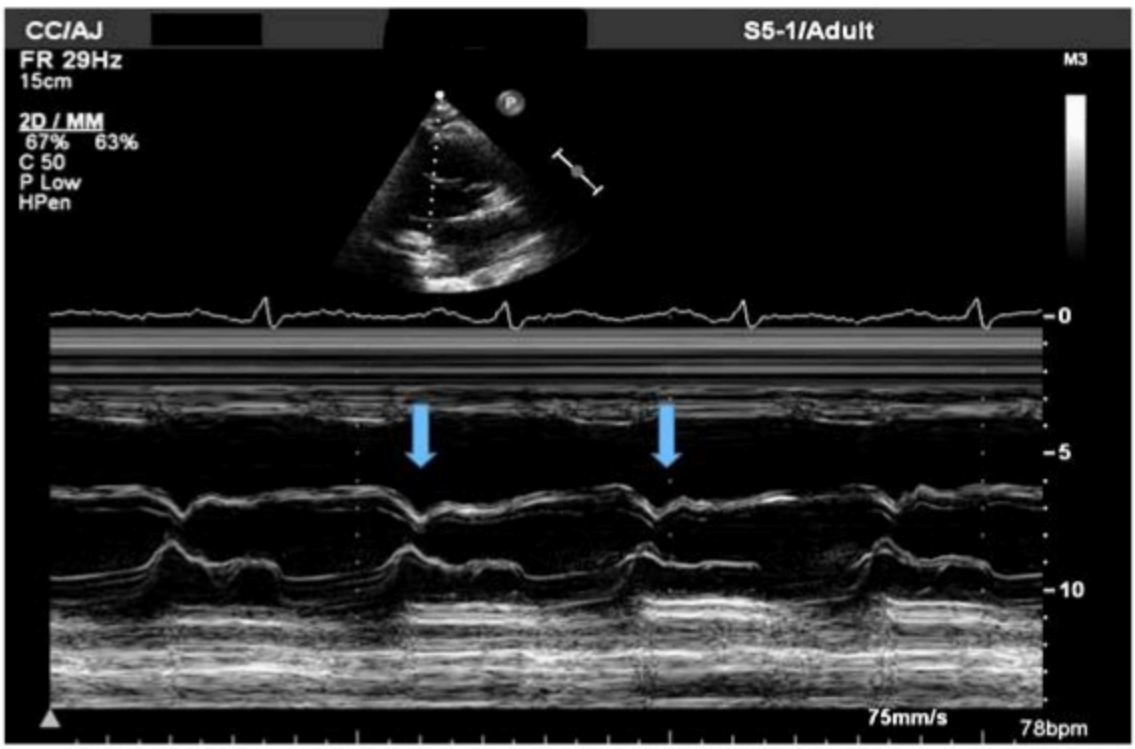

Figure 2: M Mode shows abrupt posterior septal movement during early diastole (Septal bounce, arrows)

(iii) dilatation and absent or diminished collapse of the inferior vena cava (IVC) and hepatic veins; (iv) restrictive mitral and tricuspid inflow velocities, typically (but not always) with respiratory variation (Figure 3) (6) ; (v) preserved or increased medial mitral annulus early diastolic (e´) velocity (Figure 4), which is an important distinction from restrictive cardiomyopathy in which the e´ is diminished with a cutoff value of 7 cm/sec; (vi) increased hepatic vein flow reversal with expiration, reflecting the ventricular interaction and the dissociation of the intracardiac and intrathoracic pressures (Figure 5C) (1,6) and (vii) moderate biatrial enlargement (restrictive cardiomyopathy is more often associated with severe atrial enlargement).

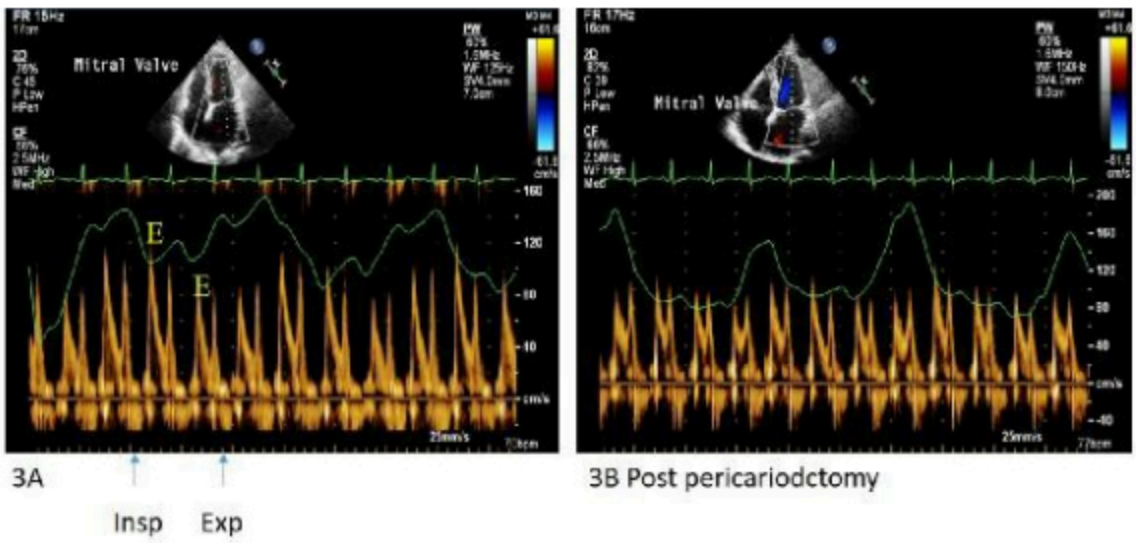

Figure 3: Respirophasic recording of mitral inflow in patient with CP before (3A) and after pericardiectomy (3B); E- early mitral flow velocity; Insp- inspiration; Exp- expiration.

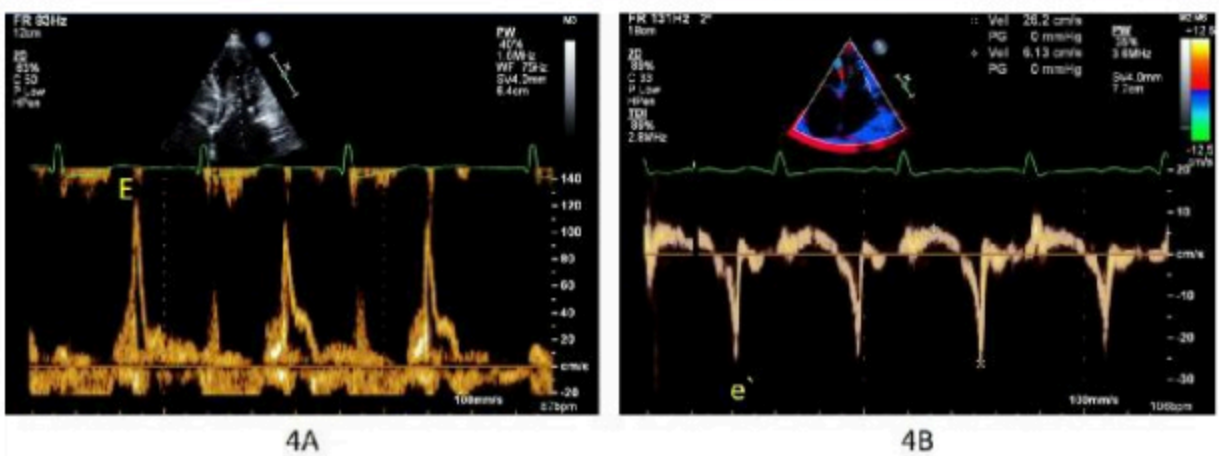

Figure 4: PW Doppler echo findings of CP are shown with high E mitral inflow velocity; short deceleration time(4A); and tissue Doppler imaging showing exaggerated lateral annular e` (4B); E- early mitral flow velocity; e`- annular tissue Doppler velocity

Septal bounce

The sign that is most obvious and should alert the echocardiographer towards the diagnosis of constriction is the abrupt posterior motion of the ventricular septum in early diastole with inspiration (septal shudder and bounce) due to the ventricular interdependence (Figure 2). The exaggerated movement of the septum to the left side is due to two factors: during inspiration, the right ventricle (RV) fills ahead of the left ventricle (LV) and pushes the septum to the left; secondly, during inspiration the intra-thoracic pressure is low, the left-side pressure difference between the pulmonary veins and the LA is reduced, therefore the mitral inflow and pulmonary

venous flow velocities decrease and this will lead to more shift of the septum to the left side. During expiration, the intra-thoracic and pulmonary veins pressure increases, hence increased flow to the LV will push the septum to the right. This septal bounce is consistent with constrictive physiology, with sensitivity of 62% and specificity of 93%.

Mitral and tricuspid flow velocities and respiratory variation

Doppler echocardiography usually shows a restrictive LV and RV diastolic filling pattern, characterized by a high early (E) velocity, a shortened deceleration time, and a reduced atrial (A) wave (Figure 4). Mitral inflow velocity usually, but not always, falls by as much as 25% to 40%, and tricuspid velocity greatly increases (>40%–60%) in the first beat after inspiration (Figure 3). (2,30. Similarly, the respiratory variation in pulmonary venous (particularly diastolic) flow is often pronounced, (14,15) similar to mitral inflow, but not always necessary for the diagnosis of constriction.

Pitfalls of respiratory variation

Mitral inflow velocities may not show respiratory variation in up to 50% patients with constrictive pericarditis as the filling pressures may be altered due to marked diuresis, which tends to reduce intrathoracic and intracardiac pressures. Therefore, the absence of respiratory variation of mitral inflow in patients with clinical evidence of significant systemic venous congestion does not exclude the diagnosis of constrictive pericarditis (3) The respiratory variation of Doppler velocities can also be seen in other conditions such as chronic obstructive lung disease, right ventricular infarct, sleep apnea, asthma, and pulmonary embolism due to increased intrapleural (intrathoracic) pressure drop with inspiration not all transmitted to heart.

Hepatic vein Doppler

Hepatic vein diastolic flow reversal increases with expiration, reflecting the ventricular interaction and the dissociation of intracardiac and intrathoracic pressures, which is essential in the diagnosis of constriction; inspiratory hepatic vein diastolic flow reversals suggest restrictive cardiomyopathy (Figure 5C).

Tissue Doppler imaging

Doppler tissue imaging is particularly useful in differentiating between CP and restrictive cardiomyopathy (16-19). Tissue Doppler shows a prominent early diastolic velocity (e`) from the medial mitral annulus, unlike

restrictive cardiomyopathy in which transmitral E is tall and narrow but tissue e` is reduced (<7 cm/sec). The usually positive linear relation between E/e` ratio and left atrial pressure, which is useful for assessing left atrial pressure in cardiomyopathy, is reversed (''annulus paradoxus'') in most patients with CP 20 because medial e` increases progressively as the severity of constriction becomes worse. Lateral mitral annular e` is usually lower than e` from the medial annulus (''annulus reversus'') due to the tethering of the lateral mitral annulus to the thickened pericardium (Figure 4) (21,22). The pericardial thickness at the left atrioventricular groove measured by CT is found to have an inverse relationship with lateral e` velocity (23). After pericardiectomy, the lateral and medial mitral annulus normalizes.

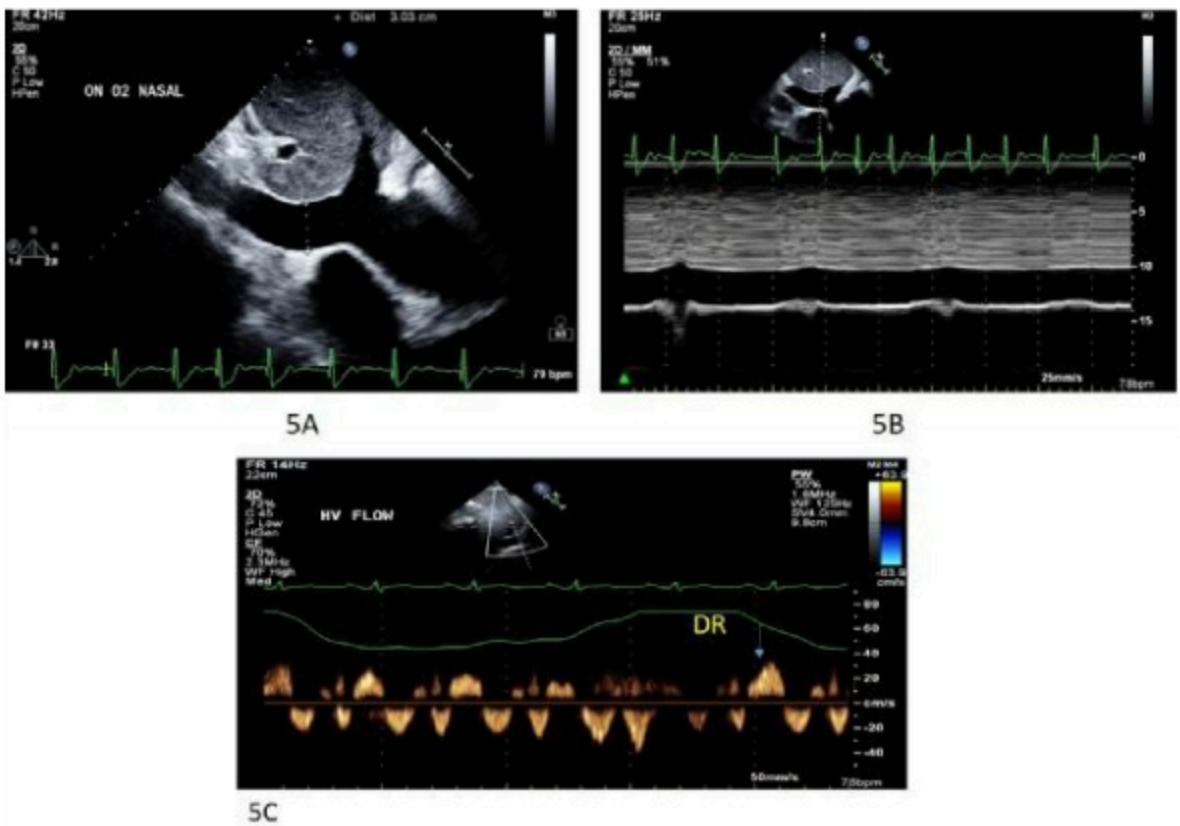

Figure 5: IVC plethora (5A) and absence of collapsibility with respiration by M mode (5B); Hepatic vein Doppler: DR- Diastolic flow reversal with expiration (5C)

2D echocardiography

Two-dimensional echocardiography reveals dilation and absent or diminished collapse of the IVC and hepatic veins (Figure 5) and moderate biatrial enlargement (severe atrial enlargement is more often associated with restrictive cardiomyopathy). LV systolic function is typically normal but may be impaired in mixed constrictive-restrictive disease, which may occur with radiation induced disease or after cardiac surgery.

Strain imaging

Differences in longitudinal and circumferential deformation may be useful to distinguish CP from restrictive

cardiomyopathy. Usually, circumferential strain, torsion, and early diastolic untwisting are reduced, and global longitudinal strain, displacement, and early diastolic tissue velocities are unchanged in constriction, whereas circumferential strain and early diastolic untwisting are preserved and longitudinal strain is reduced in restrictive cardiomyopathy (24). Recent work using speckle-tracking showed that there are significant differences in regional longitudinal systolic strain in constriction compared to restriction. The ratio of LV lateral wall strain to LV septal strain was more robust than regional annular velocity using tissue Doppler in differentiating constriction from restriction. Removal of the pericardial constraint by pericardiectomy led to improvement in longitudinal strain in the RV and LV free walls as well the circumferential strain (26). From these two studies, it can be concluded that longitudinal strains may be attenuated regionally in the free wall of the right and left ventricles, but in general, the reductions in global strains are more pronounced in constriction in the circumferential directions, whereas in restriction, they are more profoundly attenuated in the longitudinal direction (24,25).In summary, when all the echocardiographic data are taken together within a clinical context, the likelihood of constriction can usually be accurately assessed. The investigators determined that if ventricular septal shift was present with either a medial mitral annular e' velocity of 9 cm/sec or greater or a hepatic vein expiratory diastolic reversal ratio of 0.79 or greater, constrictive pericarditis could be diagnosed with a sensitivity of 87% and a specificity of 91%. If all three factors coexisted, the diagnosis could be made with a specificity of 97%, but with a sensitivity of only 64%.

Computed Tomography (CT)

CT is a highly accurate method of evaluating pericardial thickness and therefore plays an important role in the diagnosis and management of CP (25). The normal pericardium is identified as a 1 to 2 mm, whereas in CP, the parietal pericardium is usually 4 to 20 mm thick. However, 28% of 143 surgically confirmed cases had normal pericardial thickness on CT, and 18% had normal thickness on histopathologic examination (8).CT imaging can clearly delineate the presence and the exact extent of pericardial calcification (Figure 6).



Figure 6: CT of the chest showing extensive calcification of the pericardium

Irregular calcification may be found anywhere over the surface of the heart but is primarily found in regions where pericardial fat is abundant (i.e., the atrioventricular groove and base of the heart). About 50% of constriction cases show some degree of calcification. Indirect findings on CT that suggest CP include a narrowing and tubular

deformation of the right or left ventricle, normal or small ventricular size, and straightening of the interventricular septum Figure. Signs of impaired diastolic filling of the RV include dilatation of the IVC, hepatic veins, and right atrium; hepatosplenomegaly; ascites; and pleural effusions.

In addition, CT offers the ability to assess the extent of lung injury in patients with previous radiation exposure, evaluate the location and extent of pericardial calcification, and determine the need for invasive coronary angiography in those with normal results on computed tomographic coronary angiography. Failure to visualize the posterolateral LV wall on dynamic CT suggests myocardial fibrosis or atrophy and is associated with a poor surgical outcome.

Pitfalls of pericardial thickening

Thickened pericardium by CT can be found in another conditions, including the early post-operative period, uremia, rheumatic heart disease, sarcoidosis, or as a consequence of radiation therapy. Increased thickness of the pericardium per se does not constitute proof of constriction.

Cardiac magnetic resonance (CMR)

Gated CMR provides direct visualization of the normal pericardium, which is composed of fibrous tissue and has a low CMR signal intensity. CMR is advocated by some as the diagnostic procedure of choice for the detection of certain pericardial diseases, including CP. Comprehensive CMR examinations include: Bright blood cine images, Dark blood T1- and T2-weighted fast spin echo (edema images), Tagged cine images and LGE inversion recovery images. Bright blood cine images are used for assessment of atrial and ventricular size and function, diastolic restraint, diastolic septal bounce, conical deformity of the ventricles, and evidence of increased systemic venous pressure. Dark blood T1- and T2-weighted fast spin echo (edema images) is used for tissue characterization and measurement of pericardial thickness. Tagged cine images are used to evaluate for epicardial/pericardial tethering and real-time cine sequences for evaluation of ventricular interdependence. LGE inversion recovery images can be used to evaluate for both myocardial fibrosis and inflammation, as well as pericardial inflammation.

Characteristic CMR features in patients with CP include increased pericardial thickening and dilatation of the IVC. CMR better differentiates small effusions from pericardial thickening (27,28). Unlike cardiac CT, CMR does not involve exposure to ionizing radiation. CMR of the pericardium commonly demonstrates LGE in patients with CP; however, this is not a universal finding. Patients with CP and pericardial LGE have greater fibroblast proliferation, chronic inflammation, neovascularization, and pericardial thickening compared with those without LGE.

Pericardial LGE might also be a predictor of reversibility of CP after treatment with anti-inflammatory agents (Figure 7) (29,30).

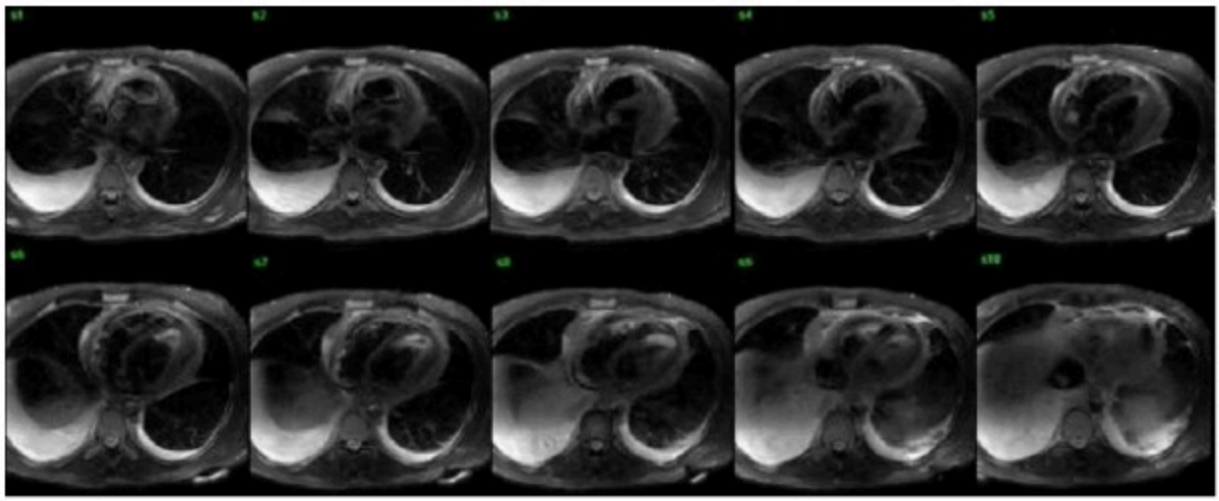

Figure 7: CMR images shows: circumferential increased thickness of the pericardium (even around the atria), maximally measures 14 mm especially over the LV free wall. In addition, there is increased pericardial T2 signal consistent with edema of the pericardium in the Fast Spin Echo Triple Inversion Recovery sequences

As described for CT, a thickened pericardium (>4 mm) in the proper clinical setting often supports the diagnosis (Figure 8). Prior studies have demonstrated that CMR has an accuracy of 93% when differentiating between CP and restrictive cardiomyopathy, using pericardial thickening of >4 mm as the cutoff (31), but it is important to emphasize that the diagnosis of CP is a clinical and hemodynamic one.

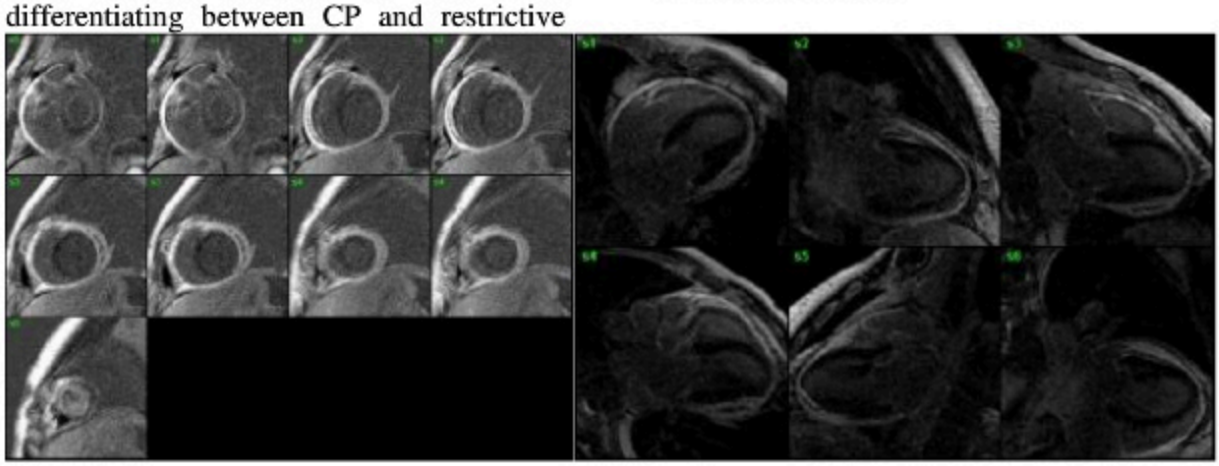

Figure 8: Myocardial delayed enhancement images, there was noticed circumferential delayed enhancement of the pericardium with localized areas of hemorrhage over the LV free wall and RV anterior wall

CMR, like echocardiography, is a functional modality with good (but inferior to echocardiography) temporal resolution, allowing the detection of hemodynamic features of constriction. These include abrupt cessation of diastolic filling, septal

bounce (32), or respirophasic variation in septal excursion, identified on real-time cine sequences. CMR myocardial tagging sequences can demonstrate pericardial-myocardial adherence. Fibrotic pericardial adhesions are present when tag deformation is absent (31-33). A recent study demonstrated that real-time phase-contrast CMR acquired over 10 seconds of unrestricted breathing and without ECG gating could demonstrate the characteristic hemodynamic changes of constrictive physiology. Respiratory variation in transmitral valve flow velocities exceeding 25% was seen in all patients with CP, and a greater variation of 45% was seen across the tricuspid valve in patients with CP. Although theoretically appealing, this sequence is not easy to use in practice, because respiration changes the position of the imaging slice with regard to the mitral and tricuspid valves, potentially influencing inflow velocities or patterns. Calculation of the maximal septal shift is easily achieved providing useful information with regard to ventricular coupling.

References

1. Ling LH, Oh JK, Breen JF, et al. Calcific constrictive pericarditis: is it still with us? Annals of internal medicine 2000;132:444-50.
2. Hatle LK, Appleton CP, Popp RL. Differentiation of constrictive pericarditis and restrictive cardiomyopathy by Doppler echocardiography. Circulation 1989;79:357-70.
3. Oh JK, Hatle LK, Seward JB, et al. Diagnostic role of Doppler echocardiography in constrictive pericarditis. Journal of the American College of Cardiology 1994;23:154157162-155160.
4. Ling LH, Oh JK, Schaff HV, et al. Constrictive pericarditis in the modern era evolving clinical spectrum and impact on outcome after pericardiectomy. Circulation 1999;100:1380-6.
5. Maisch B, Seferović PM, Ristić AD, et al. Guidelines on the diagnosis and management of pericardial diseases executive summary. European heart journal 2004;25:587-610.
6. Oh JK, Seward JB, Tajik AJ. The echo manual: Lippincott Williams & Wilkins; 2006.
7. Troughton RW, Asher CR, Klein AL. Pericarditis. The Lancet 2004;363:717-27.
8. Talreja DR, Edwards WD, Danielson GK, et al. Constrictive pericarditis in 26 patients with histologically normal pericardial thickness. Circulation 2003;108:1852-7.
9. Schnittger I, Bowden RE, Abrams J, Popp RL. Echocardiography: pericardial thickening and constrictive pericarditis. The American journal of cardiology 1978;42:388-95.
10. Agatston AS, Rao A, Price RJ, Kinney EL. Diagnosis of constrictive pericarditis by pulsed Doppler echocardiography. The American journal of cardiology 1984;54:929-30.
11. Tei C, Child JS, Tanaka H, Shah PM. Atrial systolic notch on the interventricular septal echogram: an echocardiographic sign of constrictive pericarditis. Journal of the American College of Cardiology 1983;1:907-12.
12. Hoit BD. Imaging the pericardium. Cardiology clinics 1990;8:587-600.
13. D'Cruz IA, Dick A, Gross CM, Hand CR, Lalmalani GG. Abnormal left ventricular-left atrial posterior wall contour: a new two-dimensional echocardiographic sign in constrictive pericarditis. American heart journal 1989;118:128-32.
14. Klein AL, Cohen GI, Pietrolungo JF, et al. Differentiation of constrictive pericarditis from restrictive cardiomyopathy by Doppler transesophageal echocardiographic measurements of respiratory variations in pulmonary venous flow. Journal of the American College of Cardiology 1993;22:1935-43.
15. Sun JP, Abdalla IA, Yang XS, et al. Respiratory variation of mitral and pulmonary venous Doppler flow velocities in constrictive pericarditis before and after pericardiectomy. Journal of the American Society of Echocardiography 2001;14:1119-26.
16. Garcia MJ, Rodriguez L, Ares M, Griffin BP, Thomas JD, Klein AL. Differentiation of constrictive pericarditis from restrictive cardiomyopathy: assessment of left ventricular diastolic velocities in longitudinal axis by Doppler tissue imaging. Journal of the American College of Cardiology 1996;27:108-14.

17. Ha J-W, Ommen SR, Tajik AJ, et al. Differentiation of constrictive pericarditis from restrictive cardiomyopathy using mitral annular velocity by tissue Doppler echocardiography. The American journal of cardiology 2004;94:316-9.
18. Sohn D-W, Kim Y-J, Kim H-S, Kim K-B, Park Y-B, Choi Y-S. Unique features of early diastolic mitral annulus velocity in constrictive pericarditis. Journal of the American Society of Echocardiography 2004;17:222-6.
19. Ha J-W, Oh JK, Ommen SR, Ling LH, Tajik AJ. Diagnostic value of mitral annular velocity for constrictive pericarditis in the absence of respiratory variation in mitral inflow velocity. Journal of the American Society of Echocardiography 2002;15:1468-71.
20. Ha J-W, Oh JK, Ling LH, Nishimura RA, Seward JB, Tajik AJ. Annulus paradoxus transmitral flow velocity to mitral annular velocity ratio is inversely proportional to pulmonary capillary wedge pressure in patients with constrictive pericarditis. Circulation 2001;104:976-8.
21. Reuss CS, Wilansky SM, Lester SJ, et al. Using mitral 'annulus reversus' to diagnose constrictive pericarditis. European Heart Journal-Cardiovascular Imaging 2008.
22. Veress G, Ling LH, Kim K-H, et al. Mitral and tricuspid annular velocities before and after pericardiectomy in patients with constrictive pericarditis. Circulation: Cardiovascular Imaging 2011;4:399-407.
23. Choi JH, Choi J-O, Ryu DR, et al. Mitral and tricuspid annular velocities in constrictive pericarditis and restrictive cardiomyopathy: correlation with pericardial thickness on computed tomography. JACC: Cardiovascular Imaging 2011;4:567-75.
24. Sengupta PP, Krishnamoorthy VK, Abhayaratna WP, et al. Disparate patterns of left ventricular mechanics differentiate constrictive pericarditis from restrictive cardiomyopathy. JACC: Cardiovascular imaging 2008;1:29-38.
25. Kusunose K, Dahiya A, Popović ZB, et al. Biventricular mechanics in constrictive pericarditis comparison with restrictive cardiomyopathy and impact of pericardiectomy. Circulation: Cardiovascular Imaging 2013;6:399-406.
26. Rajiah P, Kanne JP. Computed tomography of the pericardium and pericardial disease. Journal of cardiovascular computed tomography 2010;4:3-18.
27. Young PM, Glockner JF, Williamson EE, et al. MR imaging findings in 76 consecutive surgically proven cases of pericardial disease with CT and pathologic correlation. The international journal of cardiovascular imaging 2012;28:1099-109.
28. Taylor AM, Dymarkowski S, Verbeken EK, Bogaert J. Detection of pericardial inflammation with late-enhancement cardiac magnetic resonance imaging: initial results. European radiology 2006;16:569-74.
29. Feng D, Glockner J, Kim K, et al. Cardiac Magnetic Resonance Imaging Pericardial Late Gadolinium Enhancement and Elevated Inflammatory Markers Can Predict the Reversibility of Constrictive Pericarditis After Antiinflammatory Medical Therapy A Pilot Study. Circulation 2011;124:1830-7.
30. Zurick AO, Bolen MA, Kwon DH, et al. Pericardial delayed hyperenhancement with CMR imaging in patients with constrictive pericarditis undergoing surgical pericardiectomy: a case series with histopathological correlation. JACC: Cardiovascular Imaging 2011;4:1180-91.
31. Thavendiranathan P, Verhaert D, Walls MC, et al. Simultaneous right and left heart real-time, free-breathing CMR flow quantification identifies constrictive physiology. JACC: Cardiovascular Imaging 2012;5:15-24.
32. Giorgi B, Mollet NR, Dymarkowski S, Rademakers FE, Bogaert J. Clinically suspected constrictive pericarditis: MR imaging assessment of ventricular septal motion and configuration in patients and healthy subjects 1. Radiology 2003;228:417-24.
33. Oh JK, Chang S-A, Choe Y-H, Young PM. CMR Imaging for Diastolic Hemodynamic Assessment: Fantasy or Reality? JACC: Cardiovascular Imaging 2012;5:25-7.