# CASE REPORT

## Diagnosis and surgical management of a fetal cardiac tumor.

Muhieldin MM, MD, PhD. Stollery Children's Hospital, AB, CA. Email: drmuhieldin@gmail.com

Abstract
Female Infant was delivered by cesarean section at the University of Alberta Hospital secondary to concerns about fetal hydrops arising secondary to anterior Mediastinal tumor. There was apparently a
significant increase in size of this tumor about 1 week before her delivery and the plans were therefore made to deliver the child at the University Hospital and if necessary, go directly to Surgery, to remove the tumor, which was done successfully two hours after delivery. **Key words: fetal tumors; tumor surgery, endodermal sinus tumor, tumor cyst**

**Background**

Cardiac tumors were first described in the 18th century by Boneti; however, many believe the description by Albers in 1835 is the first authentic report. In 1936, the first successful removal of a neoplasm of the heart was performed. In 1952, angiography was first used for the diagnosis of heart tumors. In 1955, bypass was used for the first time to excise an intracavitary tumor (1). We are presenting a Female baby a 32-week preterm baby (corrected gestation age 37 weeks), who was diagnosed by serial fetal Echocardiograms with massive anterior medistinal tumor. Which was removed successfully surgically two hours post delivery by cesarean section Stollery Children's Hospital.

**Case history:-**

Baby delivered by cesarean section, initially was quite stable underwent a neonatal resuscitation was taken to the NICU, where the child obviously was ventilated .Initial Pco2 was 101, then improved to 75, but the child had an episode of hypotension and a repeat cardiac echocardiograms was done (Figure 1, Panel A), the echocardiograms at that time showed a massive effect on the heart and Lungs, the heart was grossly displaced and rotated, her liver was also quite enlarged well down below the costal margin. This was quite concerning and obviously there would be great risk and further medistinal rotation could result in complete occlusion of the venous and possibly the arterial system which would detrimental to the patient survival.

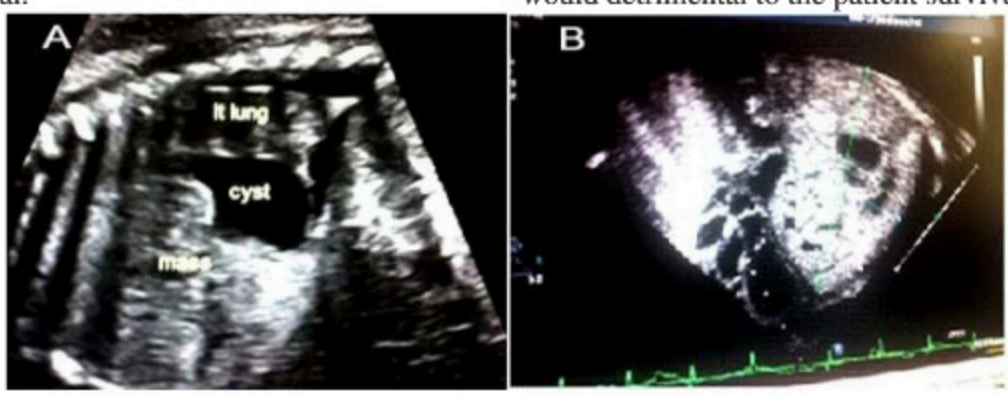


**Figure 1:** Panel A, Fetal cardiac echocardiograms. Panel B, Echocardiograms of extremely bulky tumor about (7cm X 4,5cm)

The baby was immediately taken to the operating theater for anterior medistinal tumor resection through full median sternotomy to avoid further rotation, shift to the mediastinum and myocardial compression and distortion.
The baby was already ventilated when brought to the operating theatre. Our approach was to get into the anterior mediastinum through full median sternotomy. We mobilized the pleura bilaterally, which took us down immediately onto quite a massive tumor which extended bilaterally arising mostly from the left chest but extending well into the right chest as well. We opened up the pleura over top of this and then began by medializing it first from the right side, this was facilitated by taking the majority of the thymus using electrocautery. The Thymus was handed off separately for pathologic assessment. The pleura was opened and allowed access to the anterior aspect of the mediasinum.The tumor was medialized to the right side, it was extremely bulky about (7cm X 4,5cm)(as shown by Echocardiograms in (Figure 2, Panel B) but was brought up can be seen in the intraoperative images (Figure 3,4).

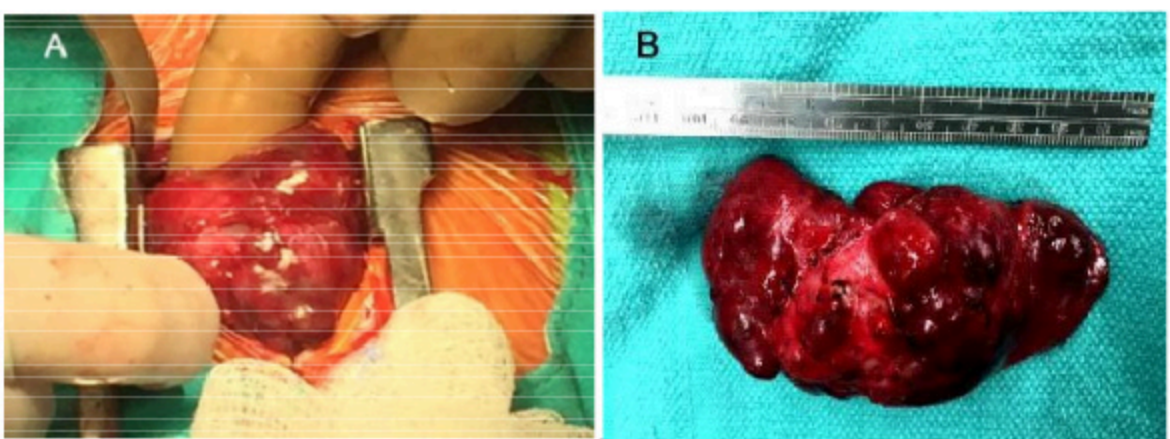


**Figure 3:** Panel A, tumor as seen intraoperatively. Panel B, Post-Operative image of the tumor.

At this stage we went on cardiopulmonaryry bypass for short period of 35 min and eventually were be able to remove the whole tumor Postoperative images of the removed tumor (Figure 5). The postoperative echocardiograms and chest CT Scan showed no more evidence of shift to the mediastinum or myocardial compression / distortion and no tumor fragments (Figure 5).
The Pathology report showed: No evidence of malignancy. An anterior mediastinum tumor of mixed germ cells with foci of yolk sac (endodermal sinus tumor), and immature teratoma.The clear fluid for Cytology showed no evidence of malignancy.

## Discussion

Cardiac Tumors in Infancy are rare (2). Prevalence rates for primary tumor of the heart and pericardium are reported from autopsy studies, in patients of all ages, as 0, 0017 % TO 0,028 % (3), even though Von Recklinghausen first described cardiac Rhabdomyomas, a common cardiac tumor in Children, in 1862(4). Since then only few cardiac tumors of childhood have been reported (5). Even less is known about fetal cardiac tumors before DeVore et al (1982) made the first diagnosis in utero of the cardiac tumor (6). Most childhood cardiac tumors are benign, with no treatment necessary unless the tumor severely obstructs blood flow or causes intractable arrhythmias. Most of them need



**Figure 5:** The postoperative chest CT scan showed no more evidence of shift to the mediastinum or myocardial compression / distortion and no tumor fragments.

only close follow-up care (7). The overall mode of treatment is variable and cannot be easily simplified as each tumor usually dictates the required treatment e.g. benign versus malignant and infiltrative versus localized. Location and extent of the tumor, as well as symptoms, are clinical variables that direct treatment therapy. In this case the cardiac tumor was massive and the echocardiograms at that time showed a massive effect on the heart and Lungs. The heart was grossly displaced and rotated and the liver was also quite enlarged well down below the costal margin. There was also a great risk of further mediastinal that may be detrimental to the child life. It is for these factors that the decision was made to intervene immediately and operate. This was successfully accomplished and the whole tumor was removed and baby discharged home in good condition. Fetal echocardiography has a very high diagnostic accuracy and may direct referral of suspected patients to large tertiary referral centers and result in a significant effect on prenatal and postnatal management outcomes.

## References

1. Tao TY, Yahyavi-Firouz-Abadi N, Singh GK, Bhalla S. Pediatric cardiac tumors: clinical and imaging features. *Radiographics*. 2014 Jul-Aug. 34 (4):1031-46.
2. Naoas AS, Ellison RC. Cardiac tumors in infancy. Am J Cardiol 1968; 21:363--6.
3. McAllister HA Jr. Primary tumors of the heart and pericardium. Pathol Annu 1979; 14:325-55.
4. Von Recklinghausen F. Ein Herz yon einem Neugeborenen welches mehrere Theils nach aussen, Theils nach den hohlen prominirende Tu.'noren (Myomen) trug. Verb Ges Geburtsh 25 Marz, Monatsschr Gebur, skd 1862; 20:1-2.
5. Van der Hauwaert LG. Cardiac tumors in infancy and childhood.Br.HeartJ. 1971; 33:125-32.

6. Simcha A, Wells BG, Tynan M J, Waterston DJ. Primary cardiac tumors in childhood. Arch Dis Child 1971; 46:508-14.

7. Amelia A, Mohd Nizam MB. Perinatal management of cardiac tumors: a case series. *Med J Malaysia*. 2013 Aug. 68(4):374-5