CASE REPORT

Intracranial neoplasm presenting as Tachycardia-bradycardia Syndrome.

Siddiq Ibrahim Khalil FRCP, FESC, FACC*. Amjad Kamal MD, DM.
Almana General Hospital, PO Box 10366, Jubail 31961, Saudi Arabia.
*Present address: The Heart Clinic, PO Box 2850, Khartoum, Sudan. Email: psiddiq@gmail.com

Abstract

23 years old male presented with palpitation headache and syncopal attacks. Clinical examination was normal except for sinus bradycardia confirmed by ECG. Holter recording showed frequent episodes of tachycardia ending abruptly into bradycardia with heart rate varying from 175 bpm to 33 bpm. MRI of brain showed midline intracranial neuroepithelial cyst at the floor of fourth ventricle pressing on medulla oblongata. We conclude that this tachycardia-bradycardia syndrome is different from that of sinus nodal dysfunction and may be due to pressure on the vasomotor centre in the medulla oblongata. Pathophysiologic association of tachycardia-bradycardia syndrome and intracranial neoplasm is discussed.

Introduction

Tachycardia-bradycardia syndrome (TBS) is a syndrome of tachyarrhythmia alternating with bradyarrhythmia. It is seen in patients with sinus node dysfunction but has rarely been described in patients with intracranial neoplasm. We report a case of TBS in a Patient with intracranial neoplasm.

Case report

Twenty three years old male presented with palpitation, headache and near syncope of three months duration. Episodes of palpitation were of sudden onset and offset and associated with episodes of headache, dizziness and pre-syncope.

There was no history of nausea, vomiting, photophobia, seizures or incontinence. There was no history of chest pain or dyspnoea. There was no history of any cardiac problem in past.

On examination pulse rate was 46/minute regular and BP was 120/70 mm Hg. There was

no carotid bruit. Systemic examination including cardiovascular and central nervous system was normal. Examination of the optic fundi was also normal. On investigation his ECG showed sinus bradycardia at a rate of 46/ minute (Figure:1panel A).

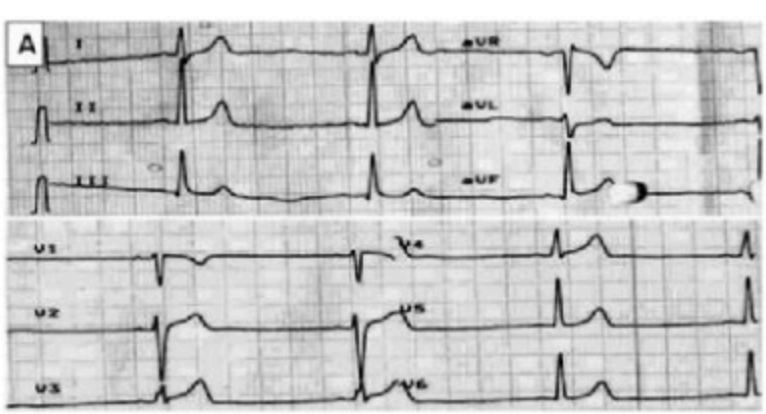

Figure 1: Panel A ECG showing sinus bradycardia with heart rate 46 bpm.

All the waveforms and intervals including QTc were normal. His echocardiogram was normal. 24 hour Holter recording showed long periods of tachycardia of sino-atrial re-entry type with sudden transition to sinus bradycardia (Figure:1 panel B).

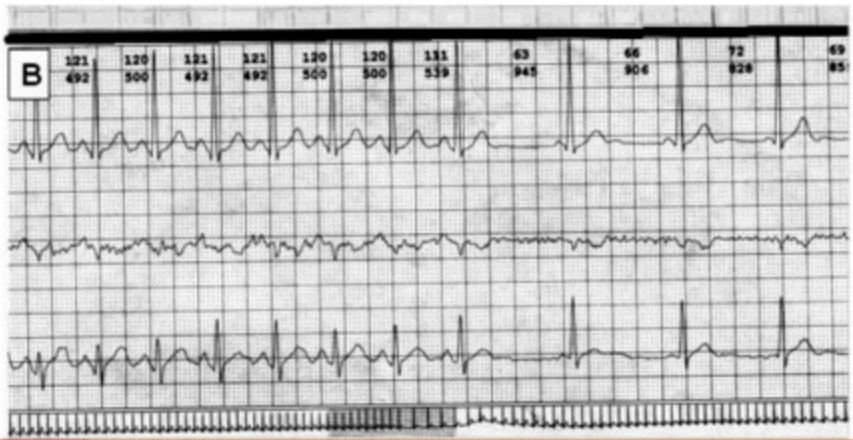

Figure 1: Panel B showing periods of tachycardia alternating with bradycardia

Thyroid function tests were normal. Manoeuvres were done to elicit autonomic reflexes by Valsalva Manoeuvre and upright tilt but were all normal. MRI of brain showed midline cystic lesion involving floor of fourth ventricle, (3×2.2×2.2 cm.) mildly pushing cerebellar vermis posteriorly and pressing the dorsal aspect of medulla oblongata resulting in anterior displacement of the body. There was no mass effect or midline shift. No hydrocephalus. The features were suggestive of neuroepithelial cyst. (Figure 2).

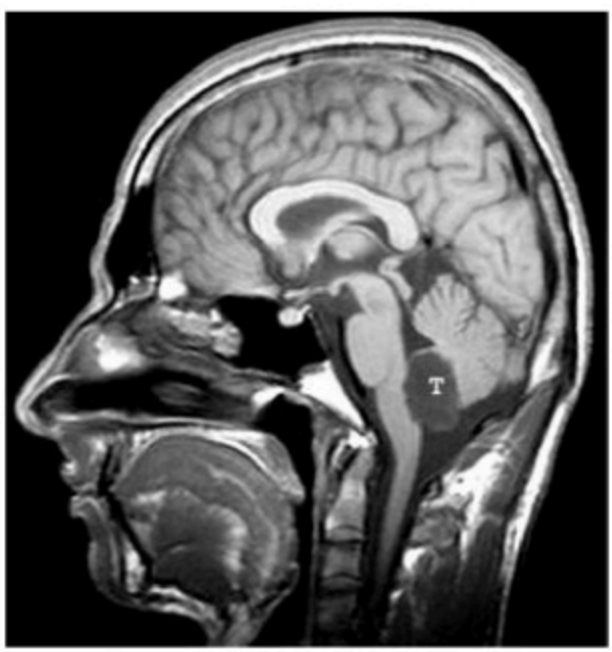

Figure 2: MRI of brain showed midline cystic lesion T involving floor of fourth ventricle, (3×2.2×2.2 cm.) mildly pushing cerebellar vermis posteriorly and pressing the dorsal aspect of medulla oblongata resulting in anterior displacement of the body.

The clinical findings and diagnosis were explained to the patient and surgical treatment was offered, however he opted not to undergo surgery at the present time.

Discussion

Young patient presented with palpitation, headache and near syncope. His episodes of palpitation correlated clinically with episodes of headache and electrocardiographically with episodes of tachycardia followed by bradycardia (so called tachy-brady syndrome or TBS) in Holter.

These TBS could happen either because of intrinsic sinus node dysfunction or from central mechanism from intracranial neoplasm. TBS seen in our patient does not appear to be from intrinsic Sinus Node Dysfunction (SND) because of many reasons among them is the young age of patient without any previous history of cardiac illness, association with episodic headache at times of arrhythmia, abrupt transition of tachycardia to bradycardia without any intervening pause or change of PR interval and no sinus pauses during period of Holter monitoring.

Intra cranial neoplasm have previously been described to be associated with bradycardia[1,2] Intra cranial neoplasm raises CSF pressure which causes bradycardia by central reflex mechanism. It may also be a manifestation of complex partial seizures.[3] or autonomic dysreflexia caused by the tumour.[4] It may also unmask intrinsic sick sinus syndrome in susceptible pateints.[5]

Intra cranial neoplasm have rarely been described to be associated with TBS. Periodic nature of tachycardia and bradycardia may be because of periodic increases in CSF pressure which is known to occur in in patients with intra cranial neoplasm.[6,7,8,9] Acute increases in intracranial pressure are known to be associated with tachycardia followed by bradycardia and are essential components of Cushing reflex.[10]

Our patient had tumour in Medulla oblongata wherein lies the Vasomotor Center (VMC). Part of VMC is concerned with control of heart rate while the other deals with constriction of blood vessels.[11] The tumor, as shown in figure 2, compresses the part of the medulla that contains the VMC. Direct pressure of this tumour on VMC along with fluctuations in CSF pressure, may be responsible for the periodic nature of the tachycardia and bradycardia.

Conclusion

This case represents unique arrhythmia characterized by a basic rhythm of sinus bradycardia with episodes of sinus tachycardia that abruptly transforms into sinus bradycardia. This appears to be different from that of intrinsic SND and may be attributable to direct tumour pressure on VMC and fluctuating CSF pressure. Consequently we conclude that intracranial causes for tachycardia-bradycardia syndrome should be considered especially when other causes are excluded by conventional investigations

References

1. Kawasaki S, IschiI M, Kon S, Yoshida Y: A case of sporadic and transient bradyarrythmias in a patient with glioma in the medulla oblongata. Kokyu To Junken 1993; 41: 787-90

2. Kasperk S, Bury W: Micturition syncope: a peculiar cause of diagnostic doubt. Cardiol Clin 1997;15(2): 177-94

3. Van der Sluijs BM, Renier WO, Kappelle AC: Brain tumor as rare cause of cardiac syncope. J.Neuoro oncol 2004; 67: 241-44

4. Finestone HM, Teesel RW: Autonomic dysreflexia after brain stem tumor resection – A case report. Am. J. Phys. Med. Rehabil. 1993; 72: 395-97

5. Takayama K, Takahato O, Sengoku K, Fujimoto K, Iwasaki H: Sick sinus syndrome after induction of anesthesia in a patient with increased intracranial pressure and ischaemic heart disease. Masui 2000; 49: 289-91

6. Galassi E, Tognetti F, Frank F, Fagioli L, Nasi MT, Gaist G : Infratentorial arachnoid cyst. J Neuro surg. 1985; 63: 210-17

7. Kaufmann H: Syncope . A neurologist viewpoint. Aviat Space Environ Med. 1994;65(6): 510-7

8. Jedynak CP, Fournier L, Fischler M, Derome P, Rougerie J, Naquet R. Loss of consciousness during benign intracranial hypertension. Correlations between CSF fluid pressure and the electroencephalogram. Boll Soc Ital Cardiol. 1977; 22(7): 1151-6 9.
9. Marshall LF, Smith RW, Shapiro HM. The influence of diurnal rhythms in patients with intracranial hypertension: implications for management. Torace. 1976;19(1-4): 47-88
10. Van Aken J, Struys M, Verplancke T, de Baerdemaeker L, Caemaert J, Mortier E. Cardiovascular changes during endoscopic third ventriculostomy. Crit. Care Med. 1992;20(7): 942-9
11. Ganong WF. Review of Medical Physiology. New York: McGraw-Hill 2001: 574-587.