CARDILOGY IMAGES

Witnessed massive pulmonary embolism

Siddiq Ibrahim Khalil FRCP, FESC, FACC*. Sahar Alfadel MD (Med)MD (Cardiology)**
*The Heart Clinic, Sayed Abdulrahman Street, PO Box 2850, Khartoum, Sudan. psiddiq@gmail.com. **Department of Cardiology, Sudan Heart Centre, Sudan. saharalfadel@yahoo.com

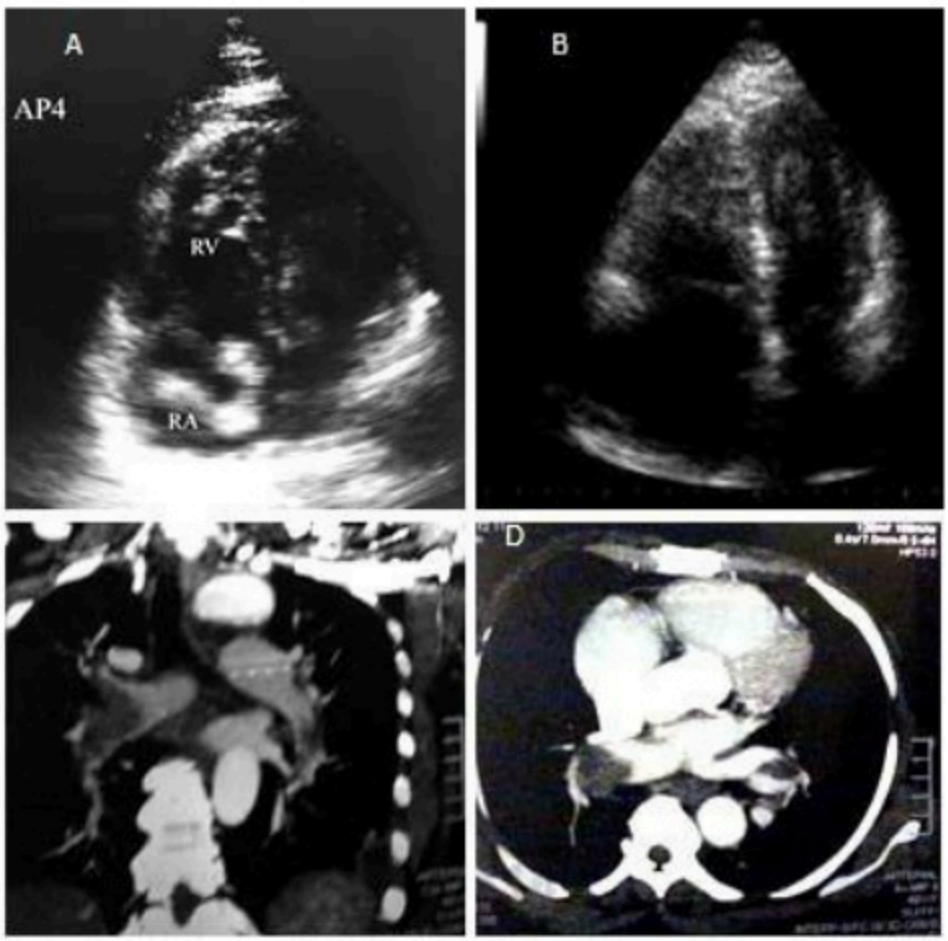

45 years old female with history of diabetes was seen by a cardiologist at a private clinic when she presented with shortness and fatigue for more than twenty hours. On physical examination she was tachypnoeic (26 breaths per minute), BP 100/60 pulse 118 bpm. Precordial examination revealed soft systolic murmur at left lower sternal edge and lung fields were bilaterally free. Oxygen saturation (room air) was 89% and ECG showed sinus tachycardia with ST segment depression and T-wave inversion from V1-V4. Transthoracic echo revealed hypermobile lobulated mass measuring 62x18mm (Panel A, Video 1). Right atrium (RA) and right ventricle (RV) were dilated and estimated pulmonary artery (PA) pressure was 46 mmHg. She was immediately rushed to the CCU at Sudan Heart Centre and upon arrival she

developed another episode of acute right sided chest pain, her condition deteriorated and was gasping for breath, BP was irrecordable and oxygen saturation dropped to 80%. ECG revealed tachycardia reaching 142 bpm in addition to deep T-wave inversion spreading from V1 to V6. Repeat echo showed severe RV dysfunction (Panel B, Video 2) and remarkably empty RA. cTroponin I level came as 1.4 ng/ml ((normal< 0.1 ng/mL)). After stabilization and treatment with Enoxparin she was rushed for contrast enhanced chest computed tomography which revealed massive pulmonary embolus (PE) nearly occluding the right main pulmonary artery (Panel C, D). Embolus on left PA was also seen, accounting for the initial attack more than twenty hours before. She was treated with tPA and Enoxparin and showed remarkable improvement.

Video 1

http://sudanheartjournal.com/media/vid1.avi

Video 2

http://sudanheartjournal.com/media/vid2.avi
