CASE REPORT

Multiple-site embolization as the initial presentation of a left atrial Myxoma

Dr. Ali Raza Rajani[1], Dr. Akram Jehad Al Rishani[2], Dr. Jumana Al Zainal[3], Dr Anas Mahmoud Abbas[2].
1 Specialist senior registrar, Rashid hospital; cardiology; Dubai – UAE
2 Specialist registrar, Rashid hospital; cardiology; Dubai – UAE
3 Intern house officer, Rashid hospital; medical department; Dubai – UAE
Correspondence: Dr Anas Mahmoud Abbas Musa: anasy120@yahoo.com

Summary:

A 51-year-old man presented with an acute onset of bilateral lower limb paresthesia that was diagnosed as acute lower limb ischemia. The diagnosis was confirmed by absent Doppler signals in the distal arteries of both lower limbs and the CT angiogram that showed blockage of left iliac and femoral arteries and right popliteal artery. He underwent urgent embolectomy and the histopathology findings of the embolus were consistent with atrial myxoma. He also developed embolization to both kidneys that resulted in acute renal failure requiring short-term hemodialysis. His transthoracic echocardiography showed small mass attached to lower interatrial septum that asserted by 2D and 3D transesophageal echocardiography to be the remnant of a left atrial myxoma attached to interatrial septum near the base of anterior mitral leaflet.

Background:

Atrial myxoma is the commonest primary cardiac tumors. Its presentation vary from asymptomatic, presenting with constitutional symptoms, cardiac failure mimicking mitral stenosis, to distal embolization [1 and 2]. It is rare that atrial myxoma presents with multiple site embolization as evident in our patient.

Case presentation:

A 51-year-old male presented with a history of acute onset of bilateral lower limb paresthesia. There was no other associated symptom. He was known to have diabetes, hypertension, dyslipidemia and bronchial asthma. He did not have any prior ischemic heart disease, arrhythmias, heart failure or any form of coagulopathy. There was no history of any recent trauma. He quit smoking two years ago.

On clinical examination, he was conscious and oriented. His heart rate was 81 beats per minute and regular, respiratory rate of 20/minute, blood pressure was 152/108 mmHg and he was afebrile. Cardiovascular and respiratory examinations were unremarkable. On examination of his lower limbs, the left leg was cold, bluish, mottled all the way to the thigh and tender on palpation. The distal pulses of left lower limbs were absent even by Doppler examination. While his right leg was warm, with no change in color but on Doppler examination, only the popliteal signal

was detected, there was no Doppler signal heard in anterior tibial artery.

Investigations and evaluation

His ECG was showing normal sinus rhythm. His hemoglobin was 12.5 g/dL, hematocrit 39.7%, white blood cells 22.7 x 103/uL, platelets 485 x 103/uL. Creatinine phosphokinase was 26330 U/L, creatinine kinase MB (CKMB) 271 U/L, troponin 1.38 ng/mL. his renal function, inflammatory markers, thrombophilia profile, and autoimmune screening were negative.

His chest x-ray was normal. However, CT angiogram and CT chest aortogram revealed a hypodense filling defect in the aorta below the level of the renal arteries causing partial occlusion of the aorta (figure 1).

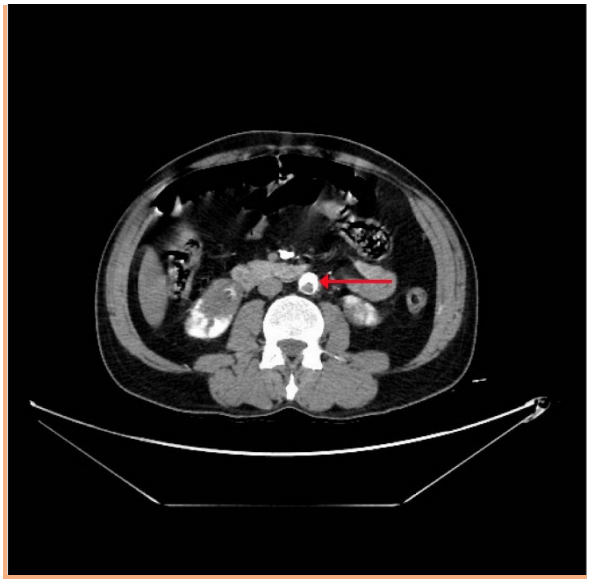

Figure 1: CT aortogram revealing filling defect in the infra-renal aorta (arrow)

There was complete occlusion of the left common iliac artery just after bifurcation of aorta extending up to the common femoral artery. There was no contrast filling seen in the distal arteries after the right popliteal artery.

Additionally, multiple bilateral wedge shaped infarcts were seen in both the kidneys (figure 2) and the spleen (figure 3).

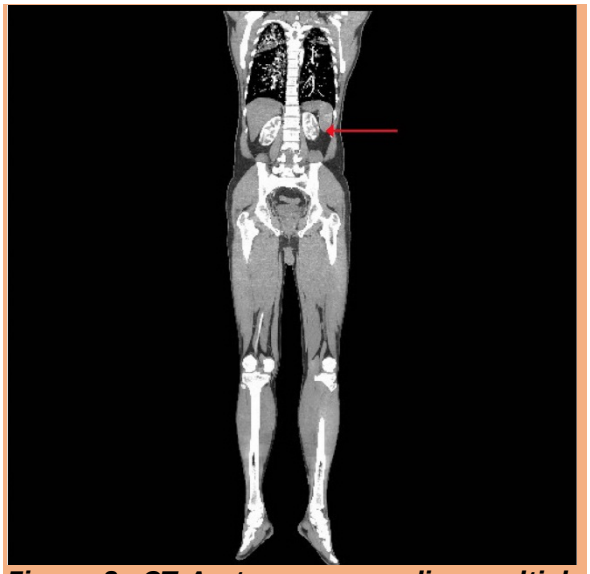

Figure 2: CT Aortogram revealing multiple infarcts in the both kidneys in coronal section (arrow)

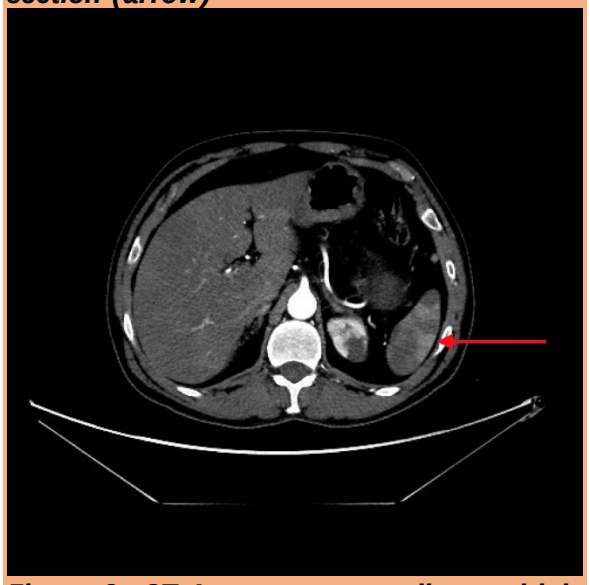

Figure 3: CT Aortogram revealing multiple infarcts in the spleen in transverse section (arrow)

The transthoracic echocardiography (TTE) showed mild left ventricular

dysfunction (with ejection fraction of 40%) with a small mass attached to the lower interatrial septum mimicking a left atrial thrombus (figure 4).

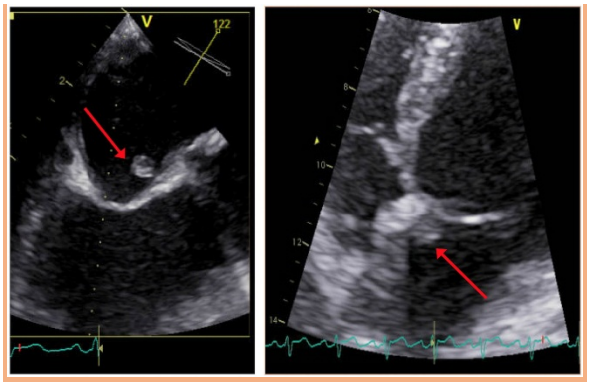

Figure 4: 2-D TTE in apical 4-chamber view and 2-D TEE showing small pedunculated myxomal mass measuring 0.8x0.6x0.5 cm attached to the lower interatrial septum on left atrial side mimicking a left atrial thrombus. (arrows)

Differential diagnoses:

1. **Atrial myxoma with multiple site embolism.**
2. **Acute arterial thrombosis.**
3. **Left ventricular clot with distal embolization.**

Management and follow up:

The patient underwent urgent embolectomy from left femoral artery and right popliteal artery along with fasciotomy of the left leg. The embolic masses from both the arteries were sent for histopathology.

The patient was intubated and treated in surgical intensive care unit with good bilateral Doppler signals. He received enoxaparin. As result of shooting up creatinine phosphokinase to 63380 U/L; he developed acute renal failure. His creatinine level went up to 6.9 mg/dL treated by hemodialysis. Then the patient recovered gradually and his creatinine came down to 1.4 mg/dL. He was extubated and started on Warfarin before the result of histopathology came confirming the diagnosis of atrial myxoma (figure 5). His follow up TEE showed remnants of left atrial cardiac myxoma (figure 6).

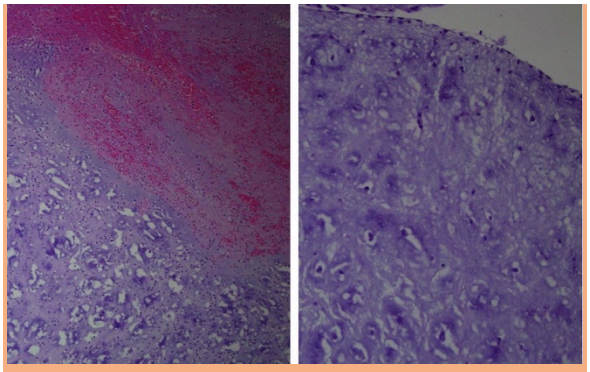

Figure 5: Histopathology of mass showing cords and isolated cuboidal cells and stellate cells. Stroma contains myxomatous material.

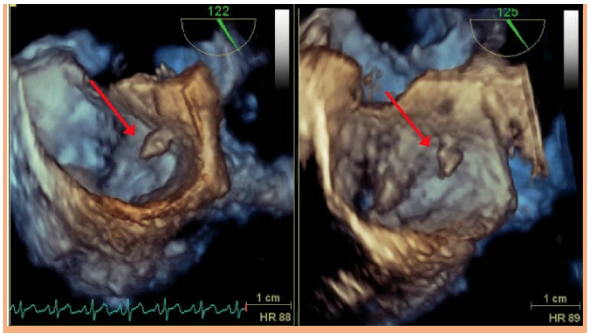

Figure 6: 3-Dimantional TEE showing the myxomatous remnant attached to the interatrial septum near the base atrial mitral leaflet.

The patient was assessed by the cardiothoracic team and advised surgical excision of the remnant of the myxoma. However, he refused to do the surgery. He was then discharged in stable condition and advised follow up echocardiography study after 6 months.

Discussion:

Cardiac tumors are very rare with an incidence rate of 0.28% on autopsied adults, 50% of which were diagnosed as atrial myxomas, marking them as the most common benign cardiac tumors [3], affecting middle-aged population (40 – 60 years), with slightly higher prevalence in females [4].

The main diagnostic method of choice of cardiac myxoma is the echocardiography. MRI and CT scans can be used for further evaluation of the mass and its extension. The treatment of atrial myxoma is surgical resection, where total excision of the mass is performed along with debridement of some of the healthy tissue [5].

Follow up echo is required to monitor for recurrence. Recurrence rate is up to 17%, possibly at the same site of the excised tumor or at other site [5].

Conservative management advised with regular echocardiography monitoring in selected group of patients including those with high operative risk, asymptomatic patients and in slow growing cardiac myxomas [6].

In earlier literature, reports of cerebral, renal and cardiac complications of AM have been documented, [7 and 8]. Hofer A. et al has reported a case of bilateral lower limb weakness caused by complete infrarenal occlusion of abdominal aorta due to embolization of cardiac myxoma. That mass was surgically removed [4]. In our case the patient presented with lower limb weakness and CT angiography showed partial occlusion of aorta.

Nicholls GM. and Clearwater G. published a similar case of atrial myxoma presented with multiple site of embolization. The patient presented with back pain and confusion, he was diagnosed as acute lower limb arterial ischemia and myocardial infarction. His CT scan showed a mass in his left atrium, there were renal and splenic infarct and embolism in left iliac artery. Urgent embolectomy and fasciotomy were performed, but his left leg could not be rescued. Then he underwent excision of the atrial myxoma [9]. In contrast to our patient who presented with acute bilateral limb ischemia whose legs were saved.

Conclusion

Atrial myxoma is a rare cardiac tumor with variable presenting symptoms, thus a high index of suspicion is required for diagnosis. Echocardiography plays a key role in the diagnosis of myxomas. Cardiac surgery is the main stay of treatment of these masses. However, the myxoma has a risk of recurrence, therefore follow up echocardiography monitoring is always required.

Learning from the case:

- **High index of suspicion is required to diagnose AM in patients presenting with multiple distal embolizationCareful transthoracic echocardiography assessment can reveal a remnant of an atrial myxoma.**
- **Early management with**

embolectomy and intensive care can improve patients' outcome and save their limbs.

References:

1. **Burke A1, Jeudy J Jr, Virmani R. Cardiac tumours: an update: Cardiac tumours. Heart. 2008 Jan;94(1):117-23.**
2. **Reynen K1. Cardiac myxomas. N Engl J Med. 1995 Dec 14;333(24):1610-7.**
3. **Molina JE, Edwards JE, Ward HB. Primary cardiac tumors: experience at the University of Minnesota. Thorac Cardio-vascSurg 1990;38 Suppl 2:183-91.**
4. **Hofer A, Hoermandinger K, Gombotz H. Bilateral Limb Ischemia and Acute Lung Edema in a Healthy Woman During Jogging. Journal of Cardiothoracic and Vascular Anesthesia. 2009;23(2):211–4.**
5. **Coley C, Lee KR, Steiner M, Thompson CS. Complete Embolization of a Left Atrial Myxoma Resulting in Acute Lower Extremity Ischemia. Tex Heart Inst . 2005;32(2):238–40.**
6. **Biswas A, Thakur A. An unusual presentation of atrial myxoma in an elderly patient: a case report. Cases J. 2008;1(1):384.**
7. **Yavuz T1, Peker O, Ocal A, Ibrisim E.; Left atrial myxoma associated with acute myocardial infarction. Int J Cardiovasc Imaging. 2005 Apr-Jun;21(2-3):235-8.**
8. **Herbst M1, Wattjes MP, Urbach H, Inhetvin-Hutter C, Becker D, Klockgether T, Hartmann A. Cerebral embolism from left atrial myxoma le ading to cerebral and retinal aneurysms. AJNR Am J Neuroradiol. 2005 Mar;26(3):666-9.**
9. **Nicholls G, Clearwater G. Emergency presentation of emboli to multiple sites from an atrial myxoma. Emergency Medicine Australasia. 2012;24(3):336-338.**