CASE REPORT

Apical hypertrophic cardiomyopathy; the good, the bad or the ugly

Safa M H Eltayeb, MRCP UK FRCP (Lond) FRCP (Glasg) Abdalla O Al Tayeb MRCP, MRXPI, M Sc, . Almana General Hospital, Dammam, Saudi Arabia. Corresponding author: safatayeb@yahoo.com

Abstract

A middle age male presented with dyspnea on exertion, chest pain and electrocardiogram (ECG) revealing inferior and anterior deep T wave inversion (TWI). He has a long standing history of hypertension. His coronary angiography revealed normal coronaries. Echocardiography (Echo) was diagnostic of apical hypertrophic cardiomyopathy (APHCM), a diagnosis which was further confirmed on cardiac magnetic resonance (CMR).

Key words: T wave inversion, apical hypertrophic cardiomyopathy, echocardiography, cardiac magnetic resonance.

Case history

A 57 years old hypertensive male presented to our emergency department with chest pain and dyspnea on exertion. He also described intermittent palpitations. His blood pressure was well controlled on Amlodipine. He has no family history of ischemic heart disease (IHD) or sudden cardiac death (SCD) , but reported that his son , a university student back at his home country , has been referred for assessment of palpitations .

Clinical examination was essentially normal .His baseline chemistry including cardiac enzymes were normal apart from a severely elevated brain natriuretic peptide level. His ECG was remarkable for severe left ventricular hypertrophy with strikingly deep TWI almost across all the leads. He was noted to have intermittent atrial fibrillation (AF) (figure 1).

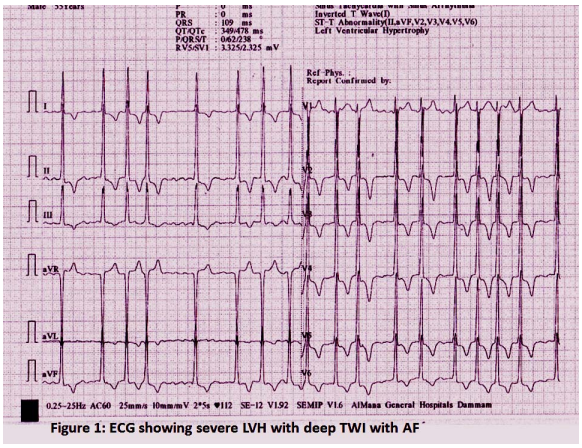

Figure 1: ECG showing atrial fibrillation and deep T wave inversion across all leads.

In view of the chest pain and ECG findings, coronary angiogram was arranged. It confirmed normal coronary anatomy. Echocardiogram was remarkable for severe hypertrophy which was preferentially apical (figure 2), extending almost from mid cavity to the apex with near cavity obliteration during systole. The interventricular septum (IVS) and Posterior wall (PW) were severely hypertrophied measuring 18 and 15 mm respectively .There was no systolic anterior motion of the mitral valve (SAM), or left

ventricular outflow tract obstruction (LVOTO) neither at rest nor with Valsalva



Figure 2: Echo showing severe apical hypertrophy of the left ventricle

augmentation. There was a mild central mitral regurgitation (MR) .The left atrium (LA) was dilated (48mm), the non- indexed volume measured at the apical 2 chamber view was 110 ml.

The echo diagnosis was confidently made as: APHCM, no obstruction.

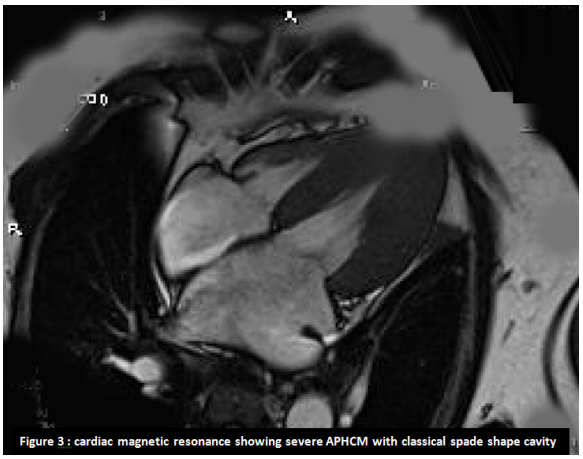

Figure 3: CMR showing APHCM with spade shape left ventricular cavity.

We arranged for a CMR. It confirmed the echo diagnosis (figure 3), the maximum measured thickness was 32 mm at the apex. The IVS and PW measurements were consistent with the echo ones. There were neither apical aneurysms nor thrombi. On late gadolinium assessment there was extensive patchy enhancement (figure 4) noted across the hypertrophied segments.



Figure 4: Gadolinium scan showing extensive enhancement across the hypertrophied segments.

We started our patient on frusemide and spironolactone. His Amlodipine was replaced with Bisoprolol. In view of paroxysmal AF anticoagulation with Apixaban was initiated.

Discussion

Since Sakamoto and Murayama published their first series of APHCM in Japan in 1976 (2) many cases were then reported worldwide. It is no longer the Japanese

version of hypertrophic cardiomyopathy. The brilliant characterization given by them (giant TWI and spade like configuration on LV angiography at the end of diastole) has stood the test of time with improvement to this description made only through cardiac imaging, removing the need for routine LV angiography.

The classical deep TWI of APHCM persists throughout life. It actually predates symptoms; hence helping in early diagnosis as well as family screening (our patient son symptoms of palpitations are alarming now that the father diagnosis is made. We advised him to pass this diagnosis to his son's physician)

Echocardiogram remains the initial step in the diagnosis. Like in our situation, it will help establishing the diagnosis and characterizing the pattern of hypertrophy (hypertrophic cardiomyopathy. Diagnosis is defined as a maximal wall thickness of 15 mm in any myocardial segment, or septum to PW thickness ratio of 1.3 in normotensive patients, or septal to PW thickness ratio of at least 1.5 in hypertensive patients (3). Measurement of 30 mm is linked to a risk of SCD.

The apex poses a special challenge during echo assessment. Foreshortening in apical views is a well-known pitfall and it is always difficult to see the true apex. The use of contrast echo has helped enormously to overcome this technical issue. Its use has increased the accuracy of diagnosing APHCM, apical aneurysms and thrombi (filling defects that don't take up the contrast) .However, both the cost and side effects stand against its routine use in many echo labs.

With its unique ability to delineate the cardiac anatomy, CMR is the gold standard for the diagnosis and risk stratification of APHCM. The true myocardium thickness across all myocardial segments , papillary muscle thickness / displacement , MV structure and function , LVOT velocity , systolic and diastolic volumes , right ventricle thickness and outflow velocity (which is not uncommonly affected in hypertrophic cardiomyopathy) , all are accurately assessed and calculated . In our case the MRI confirmed the echocardiography diagnosis of severe APHM and enabled the exact measurement of the apical thickness.

The significance of late gadolinium enhancement in severely hypertrophied ventricles has attracted a lot of interest. It is quite distinct from the pattern seen in infarctions. Many studies have linked its existence to adverse remodeling, deteriorating LV function, ventricular tachyarrhythmia and SCD. (4, 5) .Their volume is assessed by planimetry and expressed as percentage out of the LV mass. Results of ongoing studies are eagerly awaited as whether the presence of large volume of late gadolinium enhancement dictates a defibrillator insertion.

Despite the very thick wall on the apex (32 mm) along with the dilated LA both in diameter and volume, the patient doesn't qualify for implantable defibrillator. The HCM Risk of sudden cardiac death (SCD) score is a smart chart the provides a calculated 5 years risk of SCD based on: age

(the age at presentation), maximum LV wall thickness in millimeters, LA size (as determined on M-Mode on parasternal long axis view), Maximum LVOT gradient at rest and with Valsalva, Family history of SCD, Non-sustained VT or unexplained syncope. This patient calculated risk of SCD at 5 years doesn't exceed 2.45%.

AF is the commonest arrhythmia in HCM, provoked mainly by the high LA pressure and size. Once developed, it accounts for a rapid deterioration of symptoms due to loss of' atrial kick '. Thromboembolism is a substantial risk in the setting of AF (Prevalence of 27%). Older age, increased LA volume, male sex, and heart failure are predictors of thromboembolism (3). Our patient displayed the whole spectrum of the risk factors above. CHADS-VASC score is not applicable to HCM, as patients are usually younger and have not been included in the trials of thromboprophylaxis. Anticoagulation is recommended even if sinus rhythm has been achieved.

When APHCM was first reported, it was linked to a favorable prognosis compared to the obstructive phenotype. However, apical myocardial infarction, aneurysms, arrhythmias and SCD are now a well established long term complications (6).

Our patient diagnosis was made on the grounds of ECG and ECHO findings. Cardiac MRI confirmed the diagnosis and gave an accurate assessment of the extent of hypertrophy.

References

1- Sakamoto T , Tei C , Murayama M, Ichiyasu H , Hada Y. Giant T wave inversion as a manifestation of asymmetrical apical hypertrophy (AAH)of the left ventricle . Echocardiographic and ultarasound cardiotomographic study. Jpn Heart J 1976; 17:611 – 29.(PubMed).

2- Yamaguchi H, Nishiyama S , Nakanishi S , Nishimura S . Electrocardiographic, echocardiographic and ventriculographic characterization of hypertrophic non – obstructive cardiomyopathy. Eur Heart J 1983; 4 Suppl F :105-19. (Pub Med).

3- 2014 ES Guidelines on diagnosis and management of hypertrophic cardiomyopathy: the Task Force for the Diagnosis and Management of Hypertrophic cardiomyopathyof the European Society of Cardiology (ESC).Eur Heart J 2014 Oct 14; 35(39): 2733 -79 .

4- 2011 ACCF/AHA Guidelines for the Diagnosis and Treatment of Hypertrophic Cardiomyopathy: a report of the American college of Cardiology Foundation /American Heart Association Task Force on Practice Guidelines. Developed in collaboration with the American Association for Thoracic Surgery, American Society of Echocardiography, American Society of Nuclear Cardiology, Heart Failure Society of America, Heart Rhythm Society, Society for Cardiovascular Angiography and Interventions, and Society of

Thoracic Surgeons. GershBJ, Maron BJ, Bonow RO, et al. J Thorac Cardiovasc Surg. 2011 Dec; 142(6): e 153-203 .

5- American Society of Echocardiography Clinical Recommendations for Multimodality Cardiovascular Imaging of patients with Hypertrophic Cardiomyopathy. Endorsed by the American Society of Nuclear Cardiology, Society for Cardiovascular Magnetic Resonance, and Society of Cardiovascular Tomography. J Am Soc Echocardiogr 2011: 24 : 473 – 98 .

6- Eriksson MJ , Sonnenberg B, Woo A , Rakowski P , Parker T G , Wigle ED , Rakowski H . Long – term outcome in patients with apical hypertrophic cardiomyopathy. J Am Coll Cardiol 2002:39:638-45.