http://dx.doi.org/10.25239/SHJ/Vol5/No1/image2

CARDIOLOGY IMAGE

An incidental case of Idiopathic Pulmonary Artery Aneurysm

Ali Raza Rajani[1], Rabab Zaka[2], Muneeba Moin[2], Anas Mahmoud Abbas[3].
1 Specialist senior registrar, Rashid hospital; cardiology; Dubai – UAE
2 Internal medicine resident, Rashid hospital; medical department; Dubai – UAE
3 Specialist registrar, Rashid hospital; cardiology; Dubai – UAE
Correspondence: Dr Anas Mahmoud Abbas Musa; E-mail: anasy120@yahoo.com

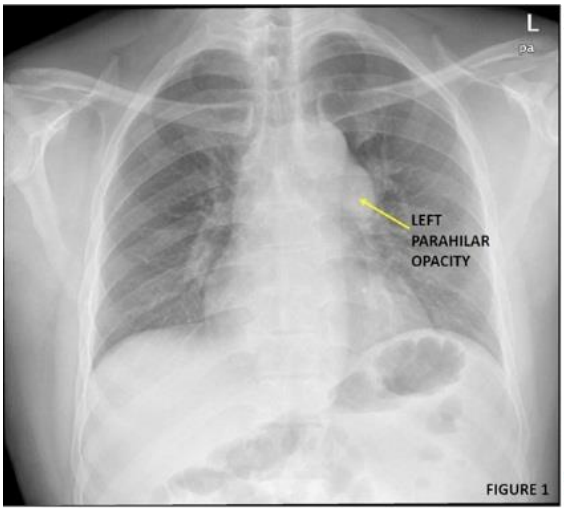

FIGURE 1

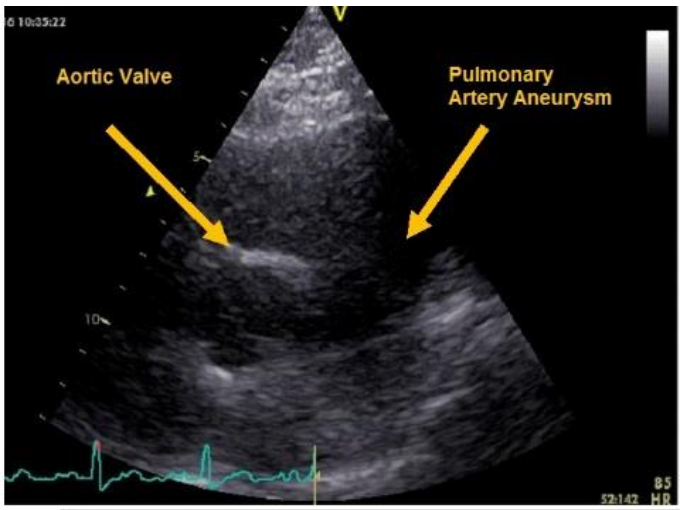



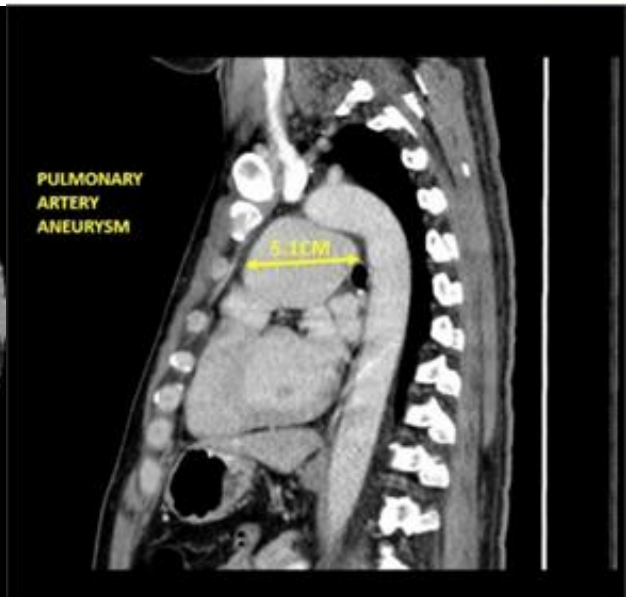

A 42-year-old male was brought to the emergency department of our hospital due to fever, confusion, abnormal behavior, and incomprehensible speech. Review of systems did not

http://dx.doi.org/10.25239/SHJ/Vol5/No1/image2

reveal any cough, shortness of breath, or hemoptysis. The patient was previously healthy and did not have any significant past medical or surgical history and he is non-smoker.

On examination, the patient's vital signs were stable and he was disoriented without focal neurological deficits and normal body habitus. He was febrile and on auscultation there was a systolic murmur mainly in the left parasternal area.

The baseline blood investigations and autoimmune workup were all normal as well as VDRL was non-reactive. His CT brain and lumbar puncture were also normal.

His routine chest X-ray revealed an incidental para-hilar opacity (image upper left) that was found related to pulmonary artery aneurysm on echocardiography (image upper right). Further evaluation by chest CT scan confirmed a 5.1-centimeter large pulmonary artery aneurysm (images lower left and right panel.

The patient presentation was due to mood disorder that was managed by psychiatrist. Cardiothoracic surgeons further evaluated the patient and recommended conservative management with regular follow-up for the incidental pulmonary artery aneurysm (PAA).