DOI: http://dx.doi.org/10.25239/SHJ/Vol6/No2/Image

Cardiology Image

Balloon Assisted Tracking to Treat Radial Artery Perforation

Author: Dr. Yassin Rufai, Dr. Afra A. M. Elhassan*, Dr. Salaheldin Abusin^*

*Fedail Hospital, Khartoum, Sudan
^Corresponding Author, salah.abusin@gmail.com

A 65-year-old female presented with history of exertional chest pain. ECG was unremarkable, Troponin was mildly increased, Echocardiogram showed normal left ventricular systolic function. Coronary Angiography via right radial artery revealed a chronic total occlusion in the left anterior descending artery (LAD) (Figure 1). PCI was attempted but complicated with vessel perforation in the right mid forearm caused by the guiding catheter (Video 1). Balloon assisted tracking with 2.0x15mm compliant balloon inflated to 8ATM over a 0.014" coronary wire at the tip of a 5F guiding catheter was performed; allowing the safe delivery of the guiding catheter to the aortic root (Video 2). PCI was performed with overlapping stents from proximal to distal LAD. Final result (Video 3) showed successful PCI, with no complications. Angiography of the radial artery showed no dye extravasation and only mild spasm consistent with sealing of the perforation. This technique was first described by Dr. Tejas Patel[1].

References:

1.Patel T, Shah S, Pancholy S, Rao S, Bertrand OF, Kwan T. Balloon-assisted tracking: a must-know technique to overcome difficult anatomy during transradial approach. Catheter Cardiovasc Interv. 2014;83(2):211-20.

DOI: http://dx.doi.org/10.25239/SHJ/Vol6/No2/Image

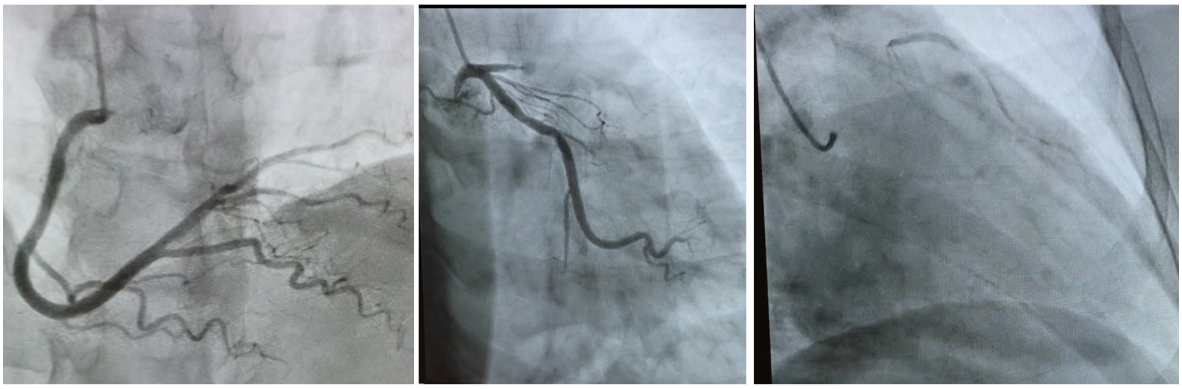

Figure 1 Chronic Total Occlusion in Proximal LAD



Video 1. Dye Extravasation (Click to view video or visit https://streamable.com/n0vks)

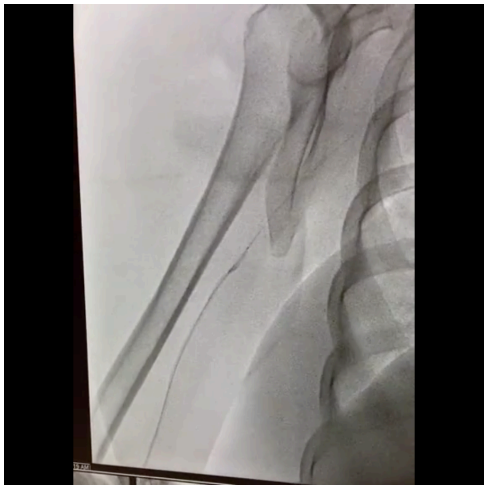

Video 2. Balloon Assisted Tracking (Click to view video or visit https://streamable.com/5u4lo)

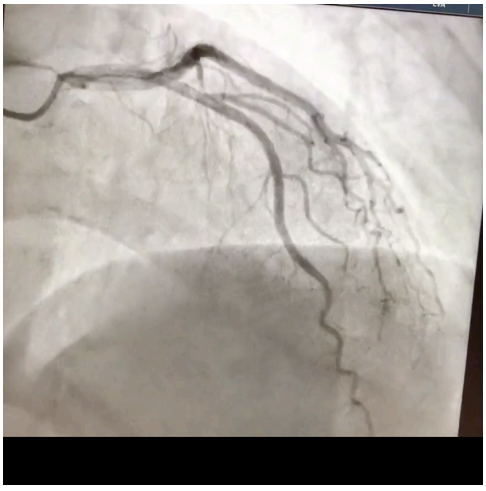

Video 3. Final Result (Click to view video or visit https://streamable.com/rnb1c)