Image

Chronic Ascending Aortic Dissection

Author(s): Dr. Galal Mohamedani^, Dr. Sara Ismael*, Dr. Elsamoual A. Abdulgadir#*

*Fedail Hospital, Khartoum, Sudan
#Sudan Heart Centre, Khartoum, Sudan
^Corresponding Author, g.mohamedani@gmail.com

A 65-year-old female with past history of Heart Failure with preserved Ejection (HFpEF), presented with HF exacerbation. Chest Xray, (Photo 1) revealed widening of the mediastinum due to unfolding of the Aorta. Echocardiography, (Video 1) demonstrated markedly enlarged Ascending Aorta with a probable dissection flap in the Ascending Aorta. The aortic valve was trileaflet with only mild regurgitation. These findings were confirmed on Contrast enhanced Computed Tomography. Her symptoms improved with diuretic therapy and BP control and was referred for elective surgical repair(1). In the operating room, direct examination (Photo 2) confirmed a chronic ascending aortic dissection with dense adhesions confined to the ascending aorta with an entry tear on the right lateral wall, 3 cm above the right coronary artery ostium. The arch was not involved, and neither was the aortic valve. It was repaired with a 30mm interposition vascular graft.

References:

1. 1.Erbel R, Aboyans V, Boileau C, Bossone E, Bartolomeo RD, Eggebrecht H, et al. 2014 ESC Guidelines on the diagnosis and treatment of aortic diseases: Document covering acute and chronic aortic diseases of the thoracic and abdominal aorta of the adult. The Task Force for the Diagnosis and Treatment of Aortic Diseases of the European Society of Cardiology (ESC). Eur Heart J. 2014;35(41):2873-926.

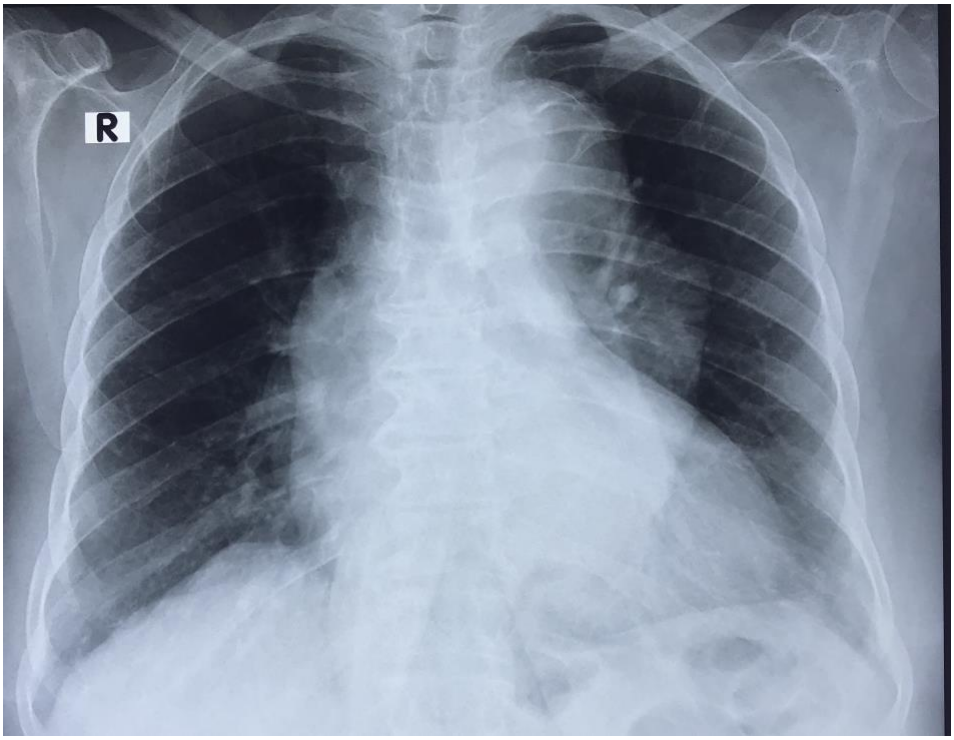

Photo 1. Chest Xray demonstrating widening of the mediastinum

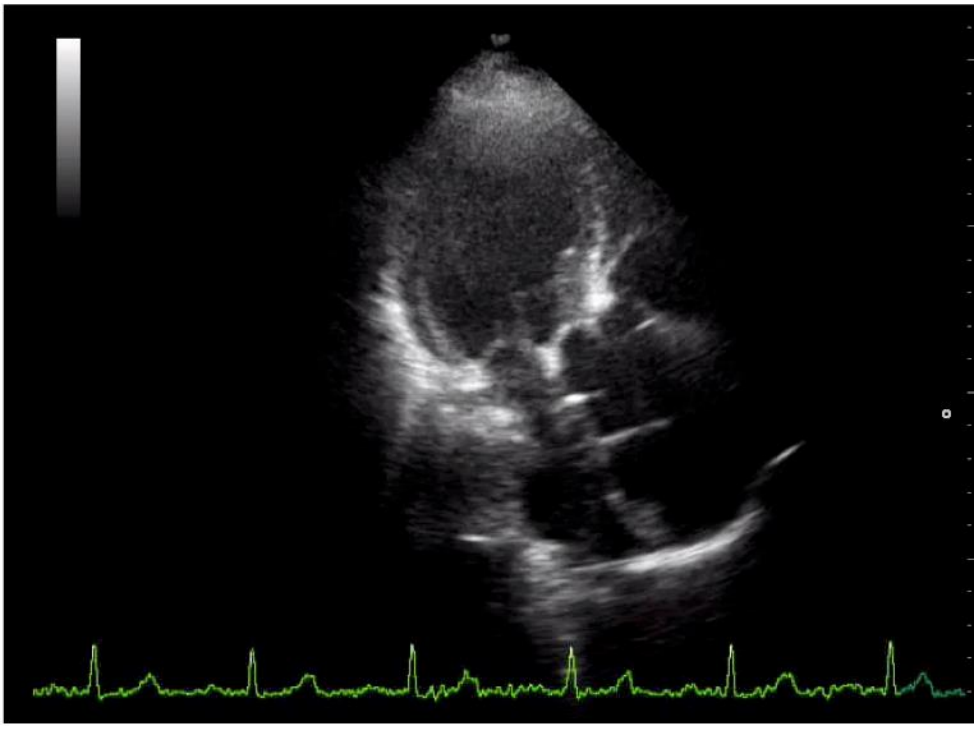

Video 1. Apical 3 chamber view demonstrating a dissection flap in the ascending aorta https://streamable.com/5qfoq

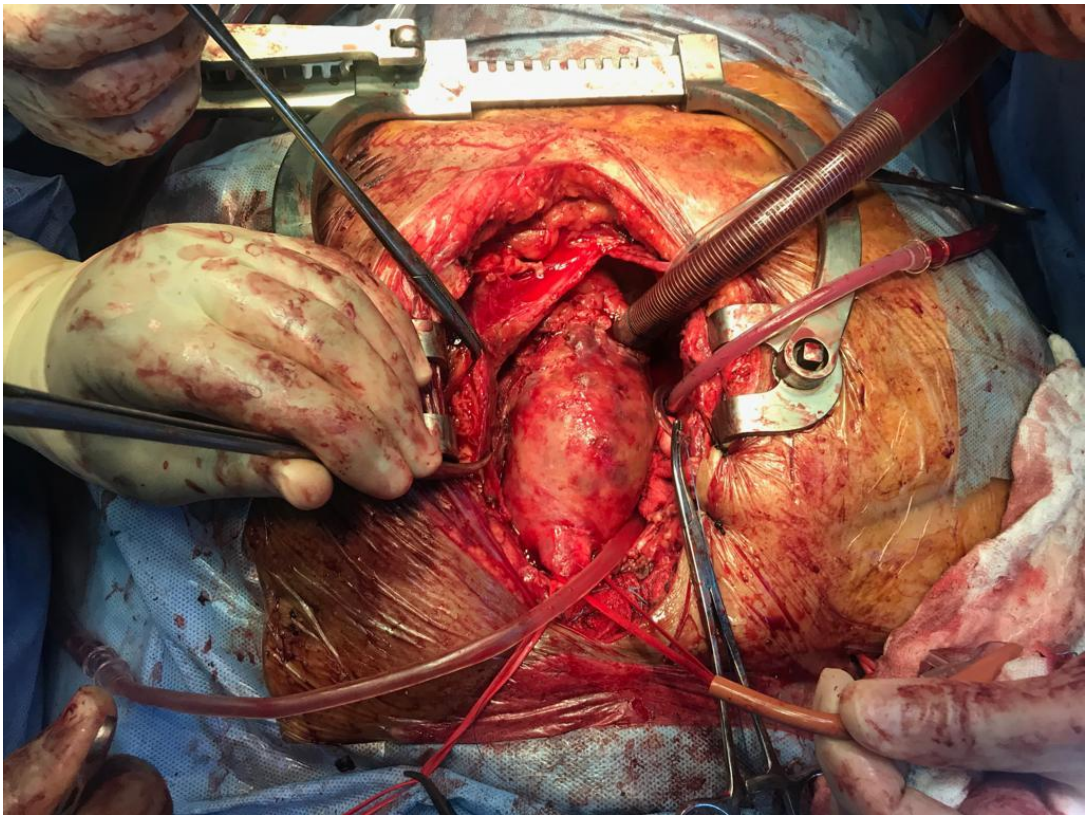

Photo 2. Operative picture demonstrating Enlarged Ascending Aorta due to Chronic Dissection