Image

Rheumatic Mitral Stenosis & Dilated Cardiomyopathy

Author(s): Mohammed Elzaki, Mohammed Salaheldin*, Salaheldin A. Abusin^**

*Fedail Hospital, Khartoum, Sudan
^Corresponding Author, salah.abusin@gmail.com

A 55-year-old male presented with history of shortness of breath on exertion. On Echocardiography, Parasternal Long Axis View (Video 1 & Video 2), revealed a severely dilated left ventricle with severely reduced systolic function, Rheumatic mitral valve stenosis with spontaneous echo contrast and mild Aortic Regurgitation. Parasternal Short Axis View of the mitral valve (Video 3), demonstrated a calcified, rheumatic mitral valve with classic fish mouth appearance. Additional echocardiography findings included: a dilated right ventricle, with reduced function, and severe pulmonary hypertension. Medical therapy for heart failure, and anticoagulation with warfarin were commenced with a plan for diagnostic coronary angiography & consideration of percutaneous mitral balloon valvuloplasty. The non-valvular etiology of the cardiomyopathy raises the possibility of two co-existing pathologies (Rheumatic Heart Disease -RHD and Dilated Cardiomyopathy) rather than attributing it to a single pathology – RHD (1, 2).

References:

1.Vasan RS, Shrivastava S, Vijayakumar M, Narang R, Lister BC, Narula J. Echocardiographic evaluation of patients with acute rheumatic fever and rheumatic carditis. Circulation. 1996;94(1):73-82.

2.Kamblock J, Payot L, Iung B, Costes P, Gillet T, Le Goanvic C, et al. Does rheumatic myocarditis really exists? Systematic study with echocardiography and cardiac troponin I blood levels. Eur Heart J. 2003;24(9):855-62.



Video 1: Parasternal Long view, Visit https://streamable.com/4vp4b to view

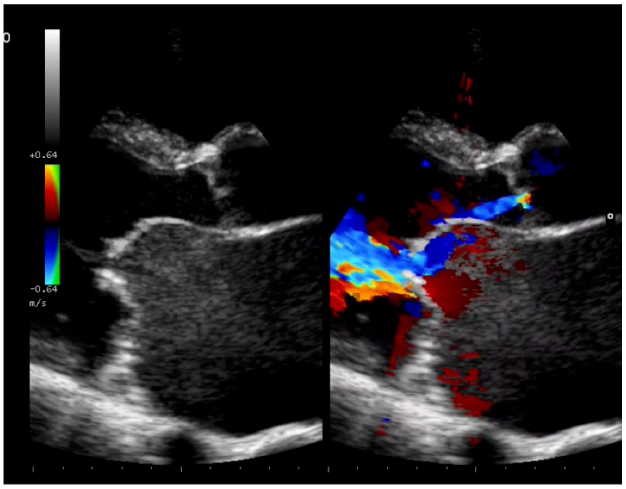

Video 2: Parasternal Long Axis View with Color doppler,

Visit https://streamable.com/r5jji to view

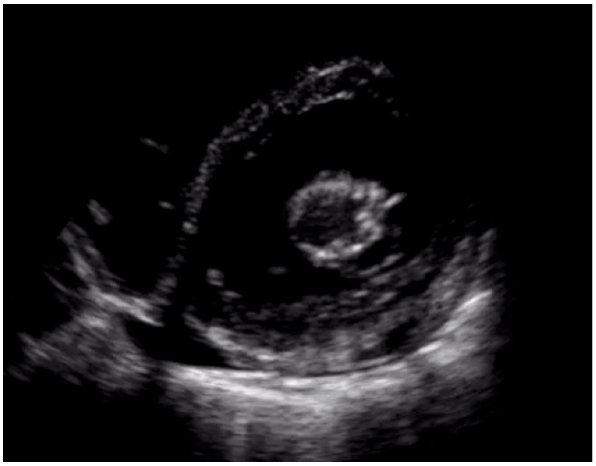

Video 3: Parasternal short axis view of the mitral valve,

Visit https://streamable.com/yn1mx to view