Case Report

Hypoxia in the time of Covid-19

Author: Abdelhaleem Bella^*

*Johns Hopkins Aramco Healthcare, Dhahran, Saudi Arabia
^Corresponding Author, abdelhaleem.bella@gmail.com

Abstract

Introduction

Since its description in December 2019 in Wuhan, China, the typical symptoms of Corona Virus Disease-2019 (Covid-19) include cough, fever, myalgia and gastrointestinal symptoms including anorexia and diarrhea with severe cases progressing to acute respiratory distress syndrome (ARDS). Dyspnea is associated with severe disease and is usually due to pneumonia which is usually multilobar and progressive. Pulmonary embolism is increasingly being reported in patients with Covid-19 and is associated with poor prognosis and increased mortality.

Case Presentation

A 56- year-old male presented with confusion and hypoxic respiratory failure without preceding symptoms of fever, cough or gastrointestinal upset. CT Pulmonary Angiogram (CTPA) showed bilateral pulmonary emboli. Nasopharyngeal and oropharyngeal swabs were positive for Severe Acute Respiratory Syndrome Corona Virus 2 (SARS-CoV-2) RNA using reverse-transcriptase-polymerase-chain-reaction assay. The author reports a case of Covid-19 associated pulmonary embolism in absence of the typical symptoms of upper or lower respiratory tract infection.

Conclusion

Pulmonary embolism is increasingly recognized in Covid-19 infection with increased mortality. The recognition of this complication leads to initiating appropriate preventive measures, early diagnosis and management.

Keywords: Covid-19, thrombosis, pulmonary embolism

Introduction

Since its description in December 2019 in Wuhan, China, the typical symptoms of Corona Virus Disease-2019 (Covid-19) include cough, fever, myalgia and gastrointestinal symptoms including anorexia and diarrhea with severe cases progressing to Acute Respiratory Distress Syndrome (ARDS). Dyspnea is associated with severe disease and is usually due to pneumonia which is usually multilobar and progressive. Pulmonary Embolism is increasingly being reported in patients with Covid-19 and is associated with poor prognosis and increased mortality.

Case Presentation

A 56-year-old male with history of hypertension, migraine and dyslipidemia was brought into the emergency department in acute confusional state. Upon arrival, his vital signs showed an oxygen saturation in room air of 84-88%, his blood pressure was low at 88/62 and he smelt of alcohol. He was afebrile, with no signs of meningeal irritation; chest examination revealed fine crackles in the left lung with no pleural rub. His Chest-X ray showed a small infiltrate in the left lung base; due to hypoxia a CT-Pulmonary Angiogram (CTPA) was done (Fig-1 A&B) which showed bilateral Pulmonary Emboli (PE). When interviewed in the morning the patient denied symptoms of fever, cough, runny nose or myalgia prior to his admission, he denied taking illicit drugs and drank his usual amount of alcohol. He was a healthcare worker and had been involved in the care of patients during the Covid-19 pandemic. He had no family history or past medical history of thromboembolic disease; he had no recent travel and was working until the day of his admission to the hospital.

Age appropriate screening for malignancy (Fecal occult blood, prostate specific antigen and colonoscopy) as well as Factor V and Factor II, were normal. CT Brain showed no intracranial bleeding and no definite evidence of an acute infarct. The toxicology screen was negative for Tricyclic Antidepressants, benzodiazepines, opiates, cannabinoids, barbiturates and methamphetamine. His biochemical profile showed normal levels of Sodium, Potassium, Chloride, Urea, Creatinine, & Magnesium. Albumin was 3.4 gm/dl , bilirubin 1.0 µmol/L, AST 72 U/L, ALT 72 U/L , LDH 332 U/L, Alcohol 288 mg/dl , BNP 13.6 pg/ml , Troponin 0.002 ng/ml. WBC count was 8,000

cells/with normal differential , Hemoglobin 14.5 g/dl and D-dimer was increased at 25.5 mg/l (Normal range 0.0-0.7 mgl/). ECG showed normal sinus rhythm, echocardiogram showed normal left ventricular systolic function, borderline dilated right ventricle with normal function, no significant valvular lesions, Pulmonary Arterial Systolic Pressure was measured at 30-35 mmHg. Since he was a healthcare worker, nasopharyngeal and oropharyngeal swabs were collected; the result came back positive for SARS-CoV-2 using reverse polymerase chain reaction (Rt-PCR). The patient was diagnosed as Covid-19 associated PE. He responded to anticoagulation with intravenous heparin following by oral Rivaroxaban. He was given empiric Tazobactam for 7 days was discharged in stable condition after spending a period of isolation until his swabs were negative for Covid-19. He continued to make an uneventful recovery and returned to work.

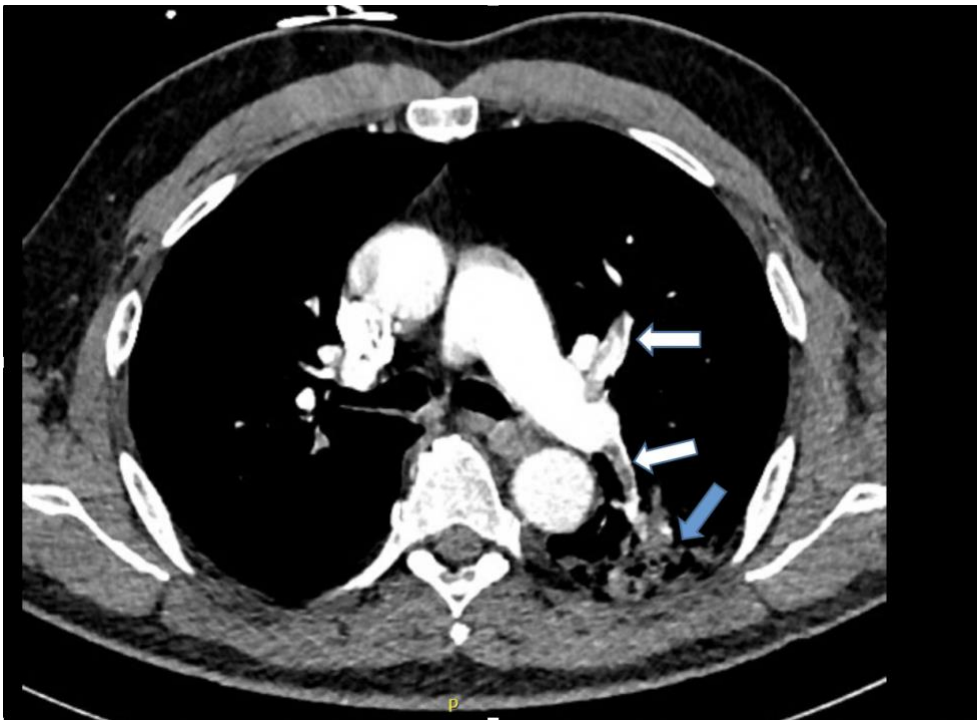

Figure 1. A. CT Pulmonary angiogram shows filling defects (white arrows) with distal infarction (blue arrow).

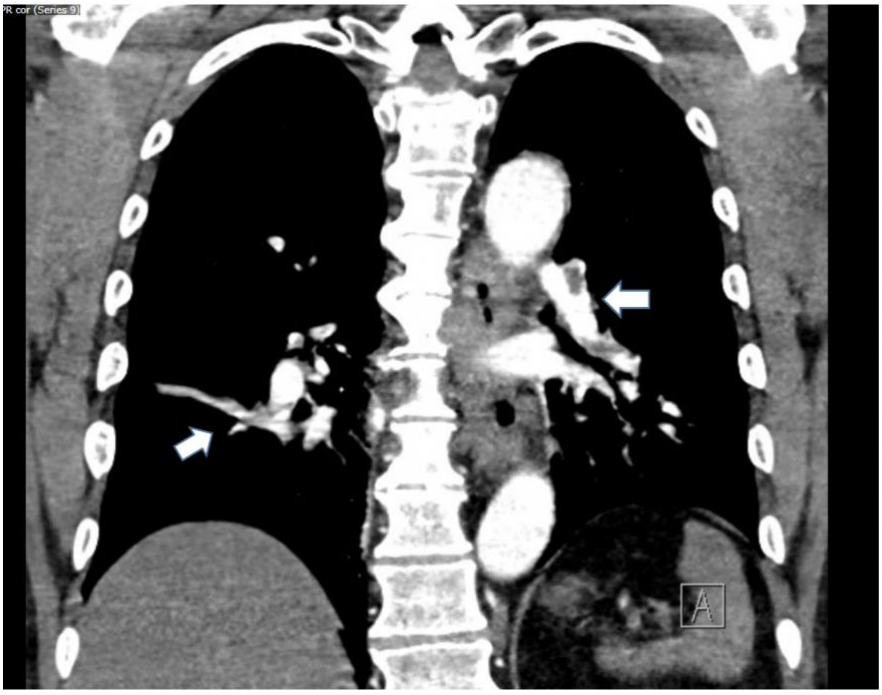

Figure 1. (B) CT Pulmonary angiogram shows bilateral filling defects (white arrows) in the pulmonary circulation.

Discussion:

Covid-19 was first described in Wuhan, Hubei Province in China in December 2019. In a large series of 72,314 patients, the majority (81%) presented with symptoms of cough , fever and dyspnea while 14% developed respiratory distress and hypoxia and 5% were critical ill with respiratory failure , septic shock and multiorgan failure (1). Severe sepsis was associated with coagulation abnormalities including Disseminated Intravascular Coagulation (DIC) and microangiopathic hemolytic anemia. Covid-19 coagulopathy is characterized by a higher D-dimer level, high ferritin, mild thrombocytopenia, high lactate dehydrogenase, and lower plasma antithrombin lower in non-survivors. Micro-vascular platelet- rich thrombotic depositions are seen in the small vessels within the lungs and other organs in absence of hemolysis. In a recent article, Covid-19 coagulopathy was described as a combination of low grade DIC and localized pulmonary microangiopathy (2). In addition to the above, high proinflammatory cytokines, such IL-1, IL-6 and Tumor Necrosis Factor-α (TNF-α)

have been reported in patients with severe Covid-19 (3). These increase the risk of thrombosis which is highest when the patient develops a cytokine storm(4). Other factors related to increased thromboembolic disease include reduced mobility and vascular access associated endothelial damage among patients managed in intensive care.

Thrombotic complications occur in 35-45% of Covid-19 patients and PE may be the culprit in the rapid deterioration of patients. In a cohort of 184 patients with severe Covid-19 in an ICU setting, 31% of them had thromboembolic disease; 27% had DVT, 3.7% had arterial thrombosis and 81% had PE (5). In an autopsy study of 12 patients, 58% had DVT which wasn't suspected antemortem and in 4 patients, PE was a direct cause of death (6). In a retrospective study of 449 patients with severe Covid-19 the patients who received heparin thromboprophylaxis had a lower mortality(7).

The International Society on Thrombosis and Haemostasis (ISTH) (8) issued guidelines on the management of thromboembolic disease in Covid-19 (Table -1).

In our patient, the initial diagnosis in the Emergency Room was alcohol intoxication, but for someone who drinks regularly; it wouldn't have explained the hypoxia. As the team were not aware that he had Covid-19 infection, a diagnosis of unprovoked PE was initially made. Since the patient was a healthcare worker and healthcare workers are at higher risk for Covid-19 infection, (In Italy, 20% of responding HCW were infected with Covid-19(9)); the diagnosis was eventually established**.** Usually patients with Covid-19 develop thromboembolic disease after presenting with typical symptoms, our patient had no Covid-19 symptoms, but still presented with significant pulmonary embolism. There is single case report of a 41 year old female who presented with massive PE secondary to Covid-19 in the absence of the typical symptoms of the disease(10).

Conclusion:

Gabriel Garcia Marquez said in his book, Love in the Time of Cholera, "*Wisdom comes to us when it can no longer do any good*." Such a paradigm of thinking is not helpful to our patients during the Covid-19 pandemic due to its associated mortality and so the need to acquire the wisdom early on and implement it is

essential. Thromboembolic disease is very common in Covid-19 and increases the risk of death, there is a need to implement thromboprophylaxis for patients with Covid-19 and to be vigilant using clinical and laboratory data (D-Dimer) to confirm the diagnosis early and treat it.

ISTH Guidance for COVID-19 Coagulopathy(8)
1. Measure D-dimer, Prothrombin Time (PT) and platelets in all patients with COVID-19 2. In patients with high D-dimers use thromboprophylaxis preferably using prophylactic dose of low molecular weight heparin (LMWH). 3. In sick patients, monitor the following: D-dimer, PT and Fibrinogen levels.

Table 1: Summary of the International Society on Thrombosis and Haemostatis (ISHT) and the American Society of Hematology Guidelines related to Covid-19 Coagulopathy

References

1.Wu Z, McGoogan JM. Characteristics of and Important Lessons From the Coronavirus Disease 2019 (COVID-19) Outbreak in China: Summary of a Report of 72 314 Cases From the Chinese Center for Disease Control and Prevention. JAMA. 2020.

2.Levi M, Thachil J, Iba T, Levy JH. Coagulation abnormalities and thrombosis in patients with COVID-19. Lancet Haematol. 2020;7(6):e438-e40.

3.Huang C, Wang Y, Li X, Ren L, Zhao J, Hu Y, et al. Clinical features of patients infected with 2019 novel coronavirus in Wuhan, China. Lancet. 2020;395(10223):497-506.

4.Mehta P, McAuley DF, Brown M, Sanchez E, Tattersall RS, Manson JJ, et al. COVID-19: consider cytokine storm syndromes and immunosuppression. Lancet. 2020;395(10229):1033-4.

5.Klok FA, Kruip MJHA, van der Meer NJM, Arbous MS, Gommers DAMP, Kant KM, et al. Incidence of thrombotic complications in critically ill ICU patients with COVID-19. Thromb Res. 2020;191:145-7.

6.Wichmann D, Sperhake JP, Lütgehetmann M, Steurer S, Edler C, Heinemann A, et al. Autopsy Findings and Venous Thromboembolism in Patients With COVID-19. Ann Intern Med. 2020.

7.Tang N, Bai H, Chen X, Gong J, Li D, Sun Z. Anticoagulant treatment is associated with decreased mortality in severe coronavirus disease 2019 patients with coagulopathy. J Thromb Haemost. 2020;18(5):1094-9.

8.Thachil J, Tang N, Gando S, Falanga A, Cattaneo M, Levi M, et al. ISTH interim guidance on recognition and management of coagulopathy in COVID-19. J Thromb Haemost. 2020;18(5):1023-6.

9.Remuzzi A, Remuzzi G. COVID-19 and Italy: what next? Lancet. 2020;395(10231):1225-8.

10.Polat V, Bostancı G. Sudden death due to acute pulmonary embolism in a young woman with COVID-19. J Thromb Thrombolysis. 2020;50(1):239-41.