Case Report

Diagnostic and Decision-Making Dilemmas in the Time of Covid-19

Author(s): Tangeni Auala, Mpiko Nteskhe *^*

*University of Cape Town & Groote Schuur Hospital, Cape Town, Republic of South Africa
^Corresponding Author, Mpiko.ntsekhe@uct.ac.za

Abstract

A 68-year-old man with cardiovascular risk factors and a history of ischemic heart disease presents with one-week history of shortness of breath, dry cough, malaise, and sore throat. Shortly after admission he deteriorates and is found to be in respiratory distress. His CXR shows bilateral infiltrates and an ECG showing inferior ST elevation Myocardial Infarction. After unsuccessful thrombolysis, he was referred for Rescue PCI. Hi Covid-19 result came back positive. This case report illustrates the complexities of diagnostic and management decision making in patients with COVID-19 infection and cardiovascular disease.

Keywords: Covid-19, Respiratory Failure, Myocardial Infarction, Pulmonary Edema

Case presentation:

Our cardiology on call team received an urgent referral for rescue percutaneous coronary intervention (PCI) for a 68-year-old male who was initially assessed as an Inferior ST Elevation Myocardial Infarction (STEMI) complicated by severe pulmonary edema and incomplete resolution of his ST segments. His past medical history was notable for Poorly Controlled Type 2 Diabetes Mellitus, Hypertension, and an Inferior Myocardial Infarction (MI) nine years prior, for which he received a bare metal stent to his mid Right Coronary Artery (RCA). He led a sedentary lifestyle and rarely left his home.

He had been admitted earlier that day to the "Patient-under-Investigation for COVID-19" ward following a week of progressive shortness of breath, dry cough, malaise, and sore throat but no chest pain. On arrival to that unit he had been hemodynamically stable,

comfortable, and free of chest pain, with unremarkable clinical examination. His room air saturation was 90%. A nasopharyngeal swab for Covid-19 PCR was requested. He was put on bed rest and managed with broad-spectrum antibiotics, Oseltamivir and 40% oxygen delivered via facemask.

Six hours after admission, his condition deteriorated significantly. He was now diaphoretic, with room air saturations of 82% and crackles at the bases, somewhat tolerated with a respiratory rate of 14 breaths per minute. ECG (Figure 1) showed sinus tachycardia at 138 beats per minute with ST elevation and T wave inversion in the inferior leads. Streptokinase was administered followed by dual antiplatelet therapy and statin. Review of his portable Chest Radiograph (Figure 2) performed a few hours earlier revealed an increased cardiothoracic ratio and diffuse bi-basal airspace opacification with areas of confluence and air bronchograms peripherally; High sensitivity Troponin T was elevated at 1248 ng/l. Repeat ECG at 90-minutes showed minimal resolution of the ST segments, as a result the referral for rescue PCI was made. He was admitted to an isolation room in the coronary care unit (CCU) under strict infection control measures, with a view to proceed to Cardiac Catheterization when the Cardiac Catheterization Laboratory (Cath Lab) became available. His Jugular Venous Pressure was elevated, he had mild bilateral pitting pedal edema, a laterally and inferiorly displaced apex beat with an S4 gallop and no murmurs. Additional tests revealed Type II Respiratory Failure (PO_2 8KPa; PCO_2 7KPa) and evidence of acute kidney injury (Urea 20.8mmol/L; Creatinine 261 µmol/L). An echocardiogram demonstrated biventricular enlargement with thinned echogenic inferior posterior (Figure 3) and lateral walls with reduced ejection fraction, estimated at 30%, an enlarged left atrium and high left ventricular filing pressures (E/E'=16mmHg).

Given his weeklong history and current clinical findings, a presumptive diagnosis of severe Covid-19 pneumonia complicated by acute Type II MI and Acute Kidney Injury was made. In view of the elevated filling pressures, it was likely that there was an element of pulmonary edema. Taking into consideration his rapidly deteriorating respiratory failure,

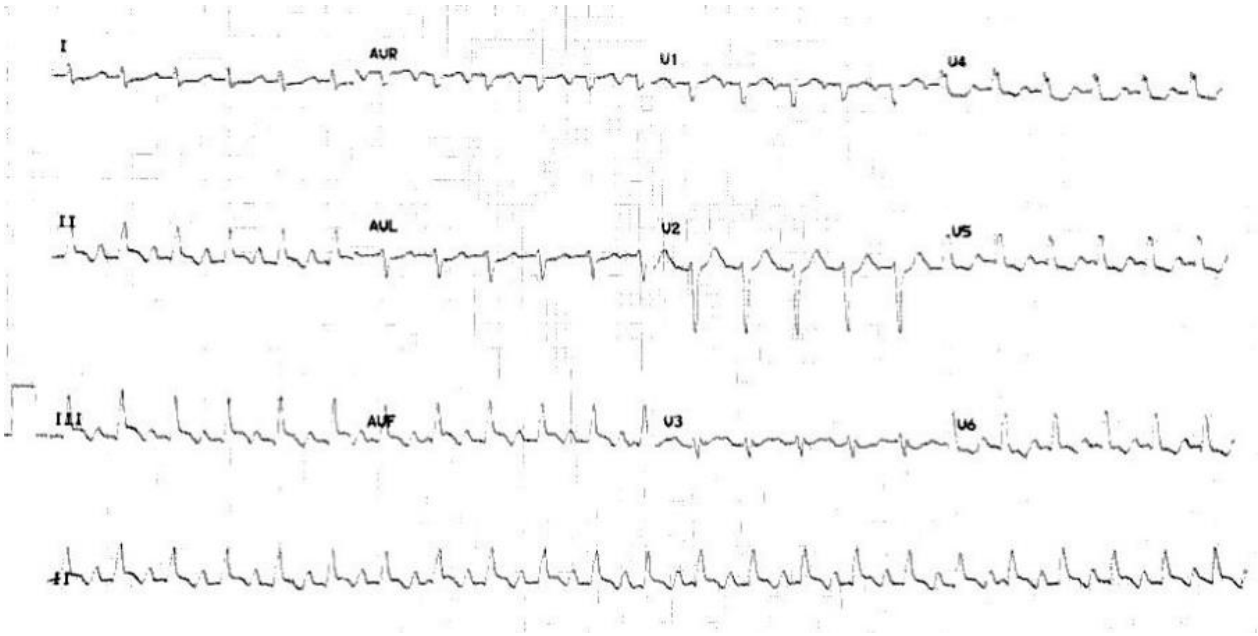

Figure 1. ECG after clinical deterioration

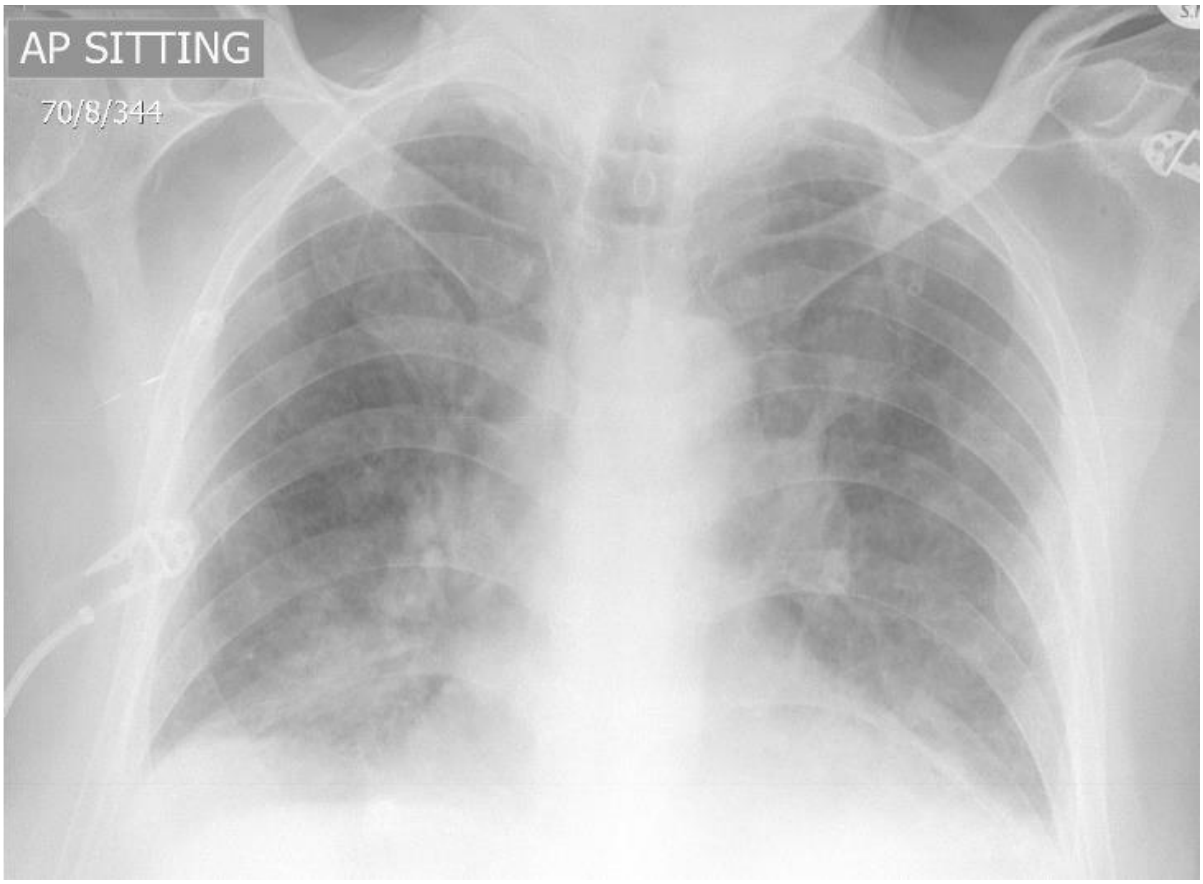

Figure 2. Chest radiograph on admission

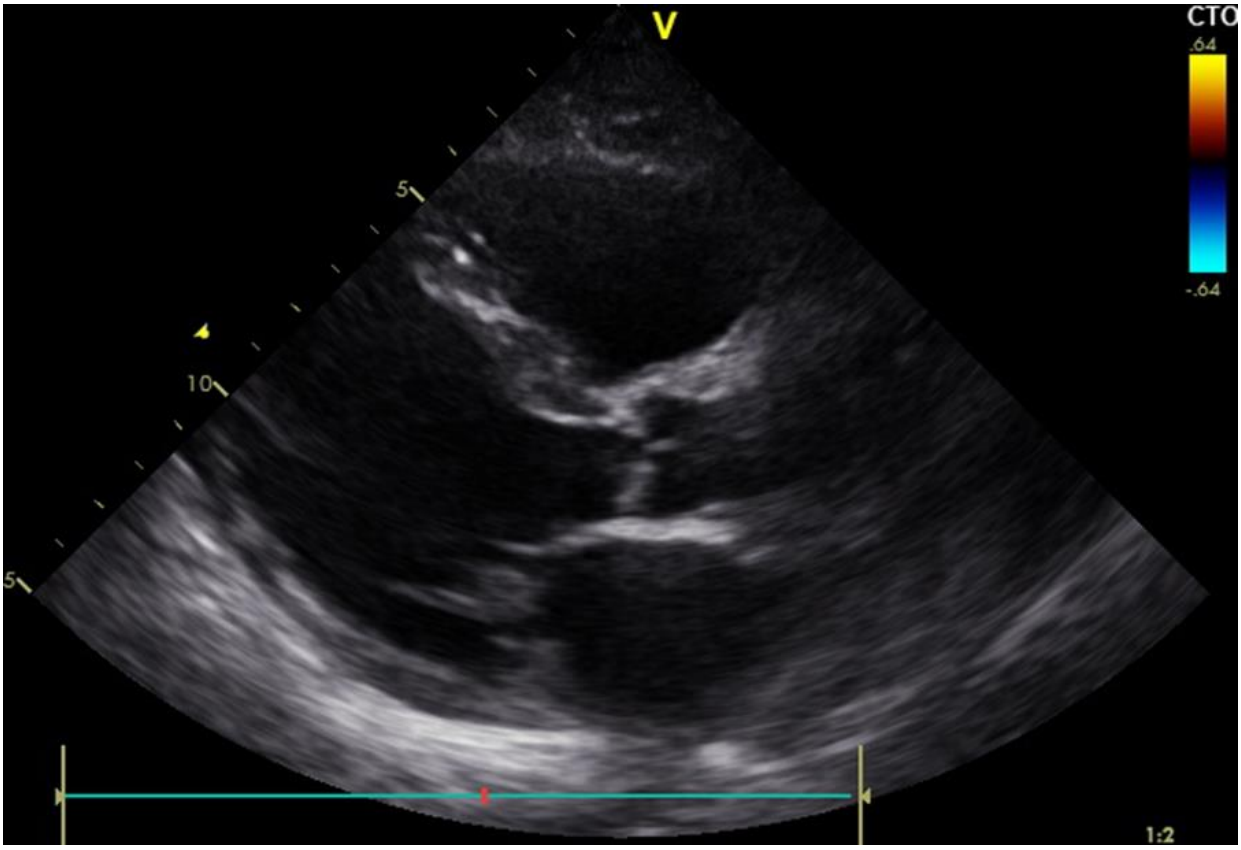

Figure 3. Transthoracic Echocardiogram , Parasternal Long Axis View

clinical diagnosis, and echo findings, the decision was taken not to proceed with Cardiac Catheterization. Intravenous furosemide was added to his management. The next morning his Covid-PCR result returned positive. He was transferred to the Covid-19 High Care Unit for high flow nasal oxygen. After evaluation by the Critical Care team, he was turned down for mechanical ventilation because of his co-morbidities and combined respiratory and cardiac failure. Over the next few days, he deteriorated further and developed multiorgan failure and succumbed to his illness on the 4th day of admission.

Discussion:

This case illustrates the significant and often underrecognized complexity of patients with Covid-19. Three aspects of the case which posed difficult decisions for the treating clinicians are worth discussing.

Differentiating Covid-19 pneumonia from Pulmonary Edema

The initial assumption was that our patient's pulmonary and radiological

findings were caused solely by Pulmonary Edema. The differential diagnosis of this patient's pulmonary findings include cardiogenic Pulmonary Edema, multifocal pneumonia, and Acute Respiratory Distress Syndrome (ARDS). In spite of history of history of ischemic heart disease, the subacute onset of respiratory symptoms, malaise, and absence of chest pain in addition to his ability to tolerate hypoxia on presentation, made the diagnosis of Covid-19 pneumonia more likely. Furthermore, when Pulmonary Edema is present, it is much more likely to follow an acute MI and not precede it as occurred in this case. His age, male gender, history of cardiovascular disease, diabetes, and hypertension all increase his risk of severe COVID-19 infection (1).

Acute pulmonary edema is unusual following an inferior STEMI unless it is complicated by acute Mitral Regurgitation, free wall rupture or pre-existing ischemic cardiomyopathy; all of which were absent in our patient. Our patient's chest radiography findings were similar to the typical pattern of bilateral, peripheral, and lower zone consolidation described in COVID-19 patients(2, 3). Acute pulmonary edema is more often characterized radiologically by bilateral perihilar infiltrates upper lobe diversion , Kerley A and B lines, peri-bronchial and perivascular cuffing and subpleural fluid(4) . Chest CT is more sensitive for early parenchymal disease in Covid-19 infection and differentiating it from acute heart failure, however, chest CT may not be readily accessible and pathologies may occur concomitantly(2).

Potential mechanisms of ST elevation and troponin release in patients with Covid-19 infection

Covid-19 infection is associated with several cardiovascular complications ranging from ischemic/non-ischemic acute myocardial injury, arrhythmia, thromboembolism, cardiogenic shock, and cardiac arrest(5).

The assessment of our case was that his respiratory failure with significant hypoxia drove his tachycardia and the combination of Systemic Inflammatory Distress Syndrome (SIRS), tachycardia, and hypoxia in a patient with underlying coronary artery disease likely precipitated a type II MI. The comparison of his past and current ECGs confirmed the presence of a previous inferior MI with residual ST elevation made more

prominent by his sinus tachycardia (Figure 4). Although a type I STEMI in the same territory cannot be excluded on ECG alone the finding of wall thinning, and akinesia were not in keeping with an ongoing STEMI. Other mechanisms of ST elevation and troponin leak in our patient include inflammatory and cytokine-mediated myocardial injury and Stress-Induced Cardiomyopathy.

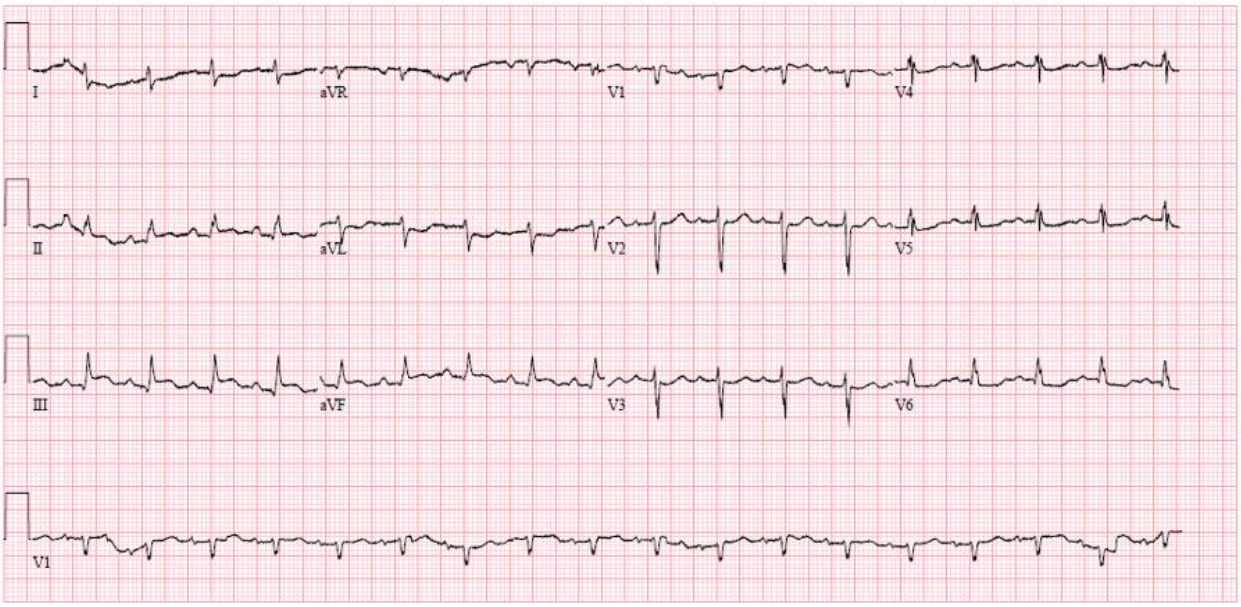

Figure 4. ECG in 2011

Decision making about taking patients with severe Covid-19 infection to the Cath lab

The decision to perform cardiac catheterization requires careful consideration of the following:

First, the balance between the potential benefit of revascularisation therapy versus his Covid-19 related prognosis. Second, the risk of exposure to SARS-COV-2 to other patients, healthcare workers and the Cardiac Cath Lab itself.

Our case also highlights the impact of the Covid-19 pandemic on health systems. As more resources continue to be mobilized to care for an increasing number of Covid-19 patients, the delivery of healthcare to patients with cardiovascular disease (CVD) is affected, particularly in resource limited settings (3) . As in our case there can be considerable overlap in the clinical presentation of COVID-19 and CVD; there may be delays in presentation and assessment of patients with CVD where clinicians have to make decisions based

on limited information (6). COVID-19 patients can develop cardiac complications and pre-existing CVD predisposes to severe Covid-19 infection and worse outcomes (3). Cooperation and access to information is crucial at all levels of healthcare provision to triage and assess patients accurately in order to facilitate prompt management of their CVD and Covid-19 infection in a manner that protects the patients from complications of either disease and limits exposure of SAR-COV-2 within healthcare facilities (3, 4).

References:

1.Zhou F, Yu T, Du R, Fan G, Liu Y, Liu Z, et al. Clinical course and risk factors for mortality of adult inpatients with COVID-19 in Wuhan, China: a retrospective cohort study. Lancet. 2020;395(10229):1054-62.

2.Zhou S, Wang Y, Zhu T, Xia L. CT Features of Coronavirus Disease 2019 (COVID-19) Pneumonia in 62 Patients in Wuhan, China. AJR Am J Roentgenol. 2020;214(6):1287-94.

3.Ng M-Y LE, Yang J, Fangfang Y et al. Imaging Profile of the COVID-19 Infection: Radiologic Findings and Literature Review. Radiology: Cardiothoracic Imaging.Vol 2(1).

4.Cardinale L, Volpicelli G, Lamorte A, Martino J, Veltri A. Revisiting signs, strengths and weaknesses of Standard Chest Radiography in patients of Acute Dyspnea in the Emergency Department. J Thorac Dis. 2012;4(4):398-407.

5.Kang Y, Chen T, Mui D, Ferrari V, Jagasia D, Scherrer-Crosbie M, et al. Cardiovascular manifestations and treatment considerations in covid-19. Heart. 2020.

6.Kazi DS, Martin LM, Litmanovich D, Pinto DS, Clerkin KJ, Zimetbaum PJ, et al. Case 18-2020: A 73-Year-Old Man with Hypoxemic Respiratory Failure and Cardiac Dysfunction. N Engl J Med. 2020;382(24):2354-64.