SUDAN HEART JOURNAL | Official Journal of the Sudan Heart Society | ISSN 1858-6783 (Print) / 1858-6791 (Online)
Vol. 9, No. 1 (Spring 2021) • Manuscript: SHJ-2021-V9N1-02 • DOI: 10.25239/SHJ/Vol9/No1/CaseReport1

Case Report

Single Coronary Artery with Triple Vessel Coronary Artery Disease: Surgical Management

Hatim Abdullahi El-Basheir[1], **Suhaib Ahmed**[2], **Alastair Graham**[2]

[1] Ahmed Gasim Cardiac Centre, Khartoum North, Sudan
[2] Royal Victoria Hospital, Belfast, UK

Correspondence: Hatim Abdullahi El-Basheir (hatim148@hotmail.com)

Abstract

We report an 80-year-old man presenting with NSTEMI found to have an isolated Lipton type L-1 single coronary artery arising from the left coronary sinus with severe atherosclerotic triple-vessel disease. Complete five-vessel CABG was successfully accomplished using sequential and individual grafts with antegrade vein-graft cardioplegia delivery to guarantee homogenous myocardial protection.

Background:

Isolated single coronary artery (SCA) is a rare anomaly in which only one coronary artery arises from the aortic trunk by a single coronary ostium and supplies the entire heart regardless of its distribution1. Lipton et al classified the anomaly into different types. In type L-1 the SCA arises from the left coronary sinus. It gives off the left anterior descending (LAD) and left circumflex (LCX) in the usual fashion. The LCX continues in the atrioventricular (AV) groove beyond the crux along the course of a normal right coronary artery (RCA) supplying its territory. Like normal coronaries these vessels can develop atherosclerotic disease. When coronary artery bypass is needed, myocardial protection can pose a special challenge. We present here our experience with one case.

Case report:

An 80 years old man was admitted to hospital following non-ST-segment elevation myocardial infarction (NSTEMI). He had no cardiac symptoms prior to that. His coronary angiogram showed type L-1 SCA with severe left main stem, LAD and LCX atherosclerotic disease. His echocardiogram showed normal left ventricular function. His serum sodium was 131 mmol/L. This was thought to be the result of being on hydrochlorothiazide for treatment of hypertension. He was referred for coronary artery bypass grafting (CABG). At operation five bypass grafts were constructed: Vein to the posterior left ventricular and then sequentially to the posterior descending artery, vein to the second obtuse marginal, vein to the first diagonal, and left internal mammary artery to mid-LAD. After each distal anastomosis cardioplaegia was delivered down the vein graft as well as the aortic root. The patient's post-operative course was complicated by fluid overload and dilutional hyponatraemia. This settled with fluid restriction and the patient made good post-operative recovery.

Discussion:

SCA is detectable in 0.014 to 0.066 while type L-1 is detectable in 0.003 to 0.014 of adult coronary angiograms2,3,4. Yamanaca et al studied 126,595 adult coronary angiograms to determine the incidence and types of coronary artery anomalies (CAAs). Anatomically they divided these anomalies into two groups: Anomalies of origin and distribution, and coronary artery fistulae. Clinically they divided the anomalies into benign and potentially serious. Type L-1 SCA was considered a benign anomaly. The same study concluded that coronary artery disease does not seem to occur with increased incidence in anomalous vessels nor does the presence of coronary anomalies protect the patient against coronary artery disease3. Rigatelly et al showed that benign CAAs are not an accelerating factor for CAD

development in patients with few or no classical risk factors5. Consequently, type L-1 SCA can remain undetected for many years as in this case.

An English literature PubMed search for articles on SCA with atherosclerotic disease was done using the term single coronary artery. The reference sections of those articles were then searched for more articles. While several reports of the use of percutaneous coronary intervention for treatment of atherosclerotic coronary artery disease were encountered, only 6 cases where coronary artery bypass grafting was used were found 4,6,7,8.

When there is severe stenosis of the SCA main stem or of the LCX, myocardial protection during CABG becomes a challenge. Adequate distribution to the RCA territory of cardioplaegia delivered down the aortic root is difficult to ensure. Retrograde cardioplaegia can't be relied upon because of the inconsistent distribution to the RCA territory9. One option to improve myocardial protection is to do the distal and proximal anastomoses sequentially8, starting with the LCX/RCA territory. This will ensure adequate delivery to the RCA territory of cardioplaegia delivered into the aortic root. Another option, which is the one we used in this case, is that once the distal anastomosis is done the proximal end of the vein is connected to the cardioplaegia delivery system for ante-grade delivery of cardioplaegia down vein grafts. This strategy worked well in our case.

Conclusion:

Type L-1 SCA is a rare anomaly. When CABG is needed for treatment of atherosclerotic disease, ante-grade delivery of cardioplaegia down vein grafts is a good myocardial protection strategy.

References:

Lipton M, Barry W, Obrez I, Silverman J, Wexler L. Isolated single coronary artery: Diagnosis, angiographic classification, and clinical significance. Radiology. 1979;130:39-47.

Akcay A, Tuncer C, Batyraliev T, Gokce M, Eryonucu B, Koroglu S, Yilmaz R.

Isolated single coronary artery: a series of 10 cases. Circ J. 2008 Aug;72(8):1254-8.

Yamanaka O, Hobbs RE. Coronary artery anomalies in 126,595 patients undergoing coronary arteriography. Cathet Cardiovasc Diagn. 1990 Sep;21(1):28-40.

Desmet W, Vanhaecke J, Vrolix M, Van de Werf F, Piessens J, Willems J, de Geest H. Isolated single coronary artery: a review of 50,000 consecutive coronary angiographies. Eur Heart J. 1992 Dec;13(12):1637-40.

Rigatelli G, Gemelli M, Zamboni A, Docali G, Rossi P, Rossi D, Grazio M, Franco G, Rigatelli G. Are coronary artery anomalies an accelerating factor for coronary atherosclerosis development? Angiology. 2004 Jan-Feb;55(1):29-35.

Vrolix MC, Geboers M, Sionis D, De Geest H, Van de Werf F. Right coronary artery originating from distal left circumflex: an unusual feature of single coronary artery. Eur Heart J. 1991 Jun;12(6):746-7.

Asha M, Sriram R, Mukundan S, Abraham KA. Single coronary artery from the left sinus with atherosclerosis. Asian Cardiovasc Thorac Ann. 2003 Jun;11(2):163-4.

Zhidong Y, Fei W, Fan L, Ming Z, Fenglin W. Surgical treatment of single coronary artery anomaly complicated with atherosclerotic coronary artery disease. Chinese Medical Journal. 1999;112(7):671-672.

Borger MA, Wei KS, Weisel RD. Myocardial perfusion during warm antegrade and retrograde cardioplaegia: a contrast echo study. Ann Thorac Surg 1999;68:955-61.

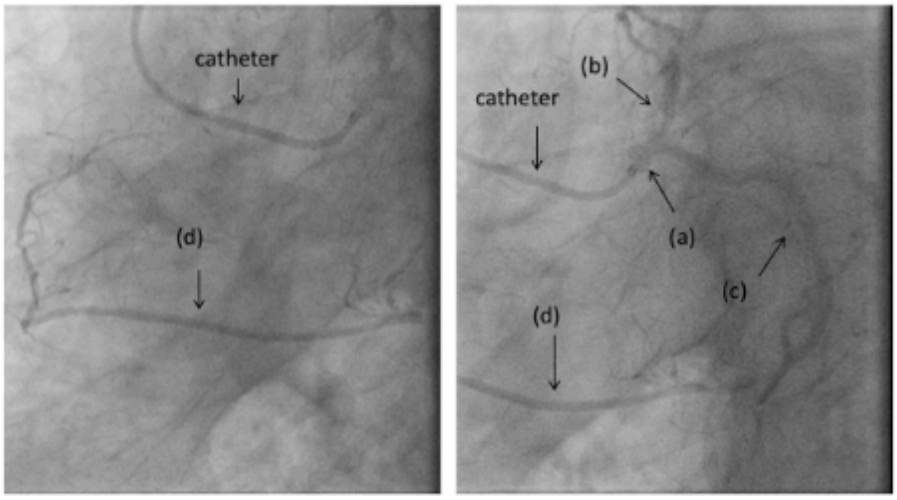

Figure (1): Spider view of left coronary system showing: (a) left main stem, (b) left anterior descending artery , (c) circumflex artery, (d) right coronary artery

Figure 1: Preoperative Coronary Angiogram Showing Lipton Type L-1 Single Coronary Artery

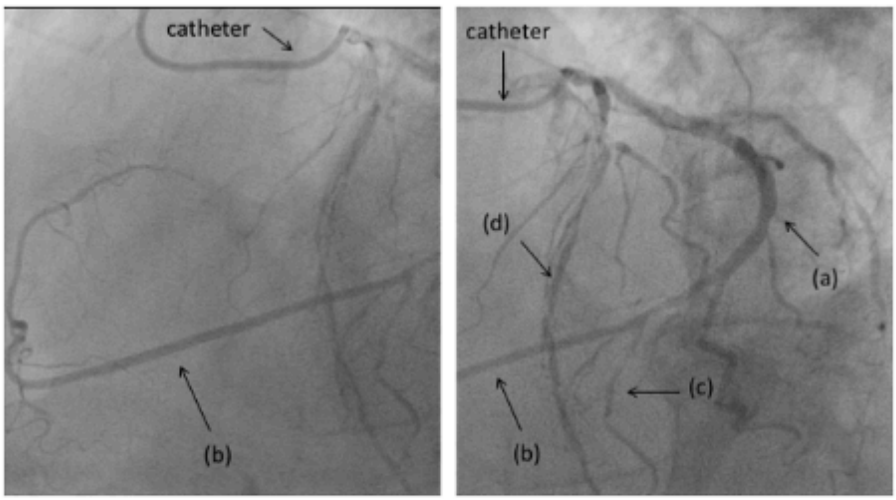

Figure (2): Left anterior oblique view of the left coronary system showing: (a) circumflex artery, (b) right coronary artery, (c) posterior descending coronary artery, (d) left anterior descending artery.

Figure 2: Single Coronary Ostium Giving Off Diseased LAD & Circumflex Branches

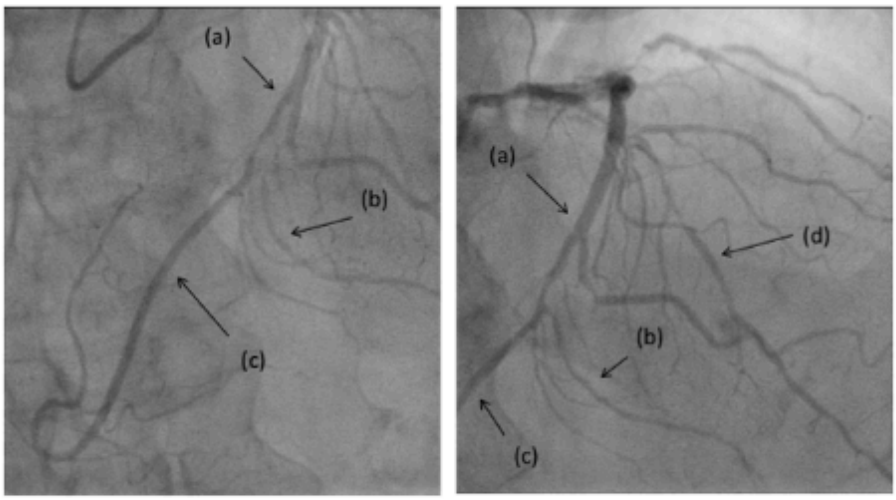

Figure (3): Right anterior oblique view of the left coronary system showing: (a) circumflex coronary artery, (b) posterior descending artery, (c) right coronary artery, (d) left anterior descending artery.

Figure 3: Intraoperative / Angiographic Collateralization Across RCA Territory